



ECVP/ESVP Summer School in Veterinary Pathology

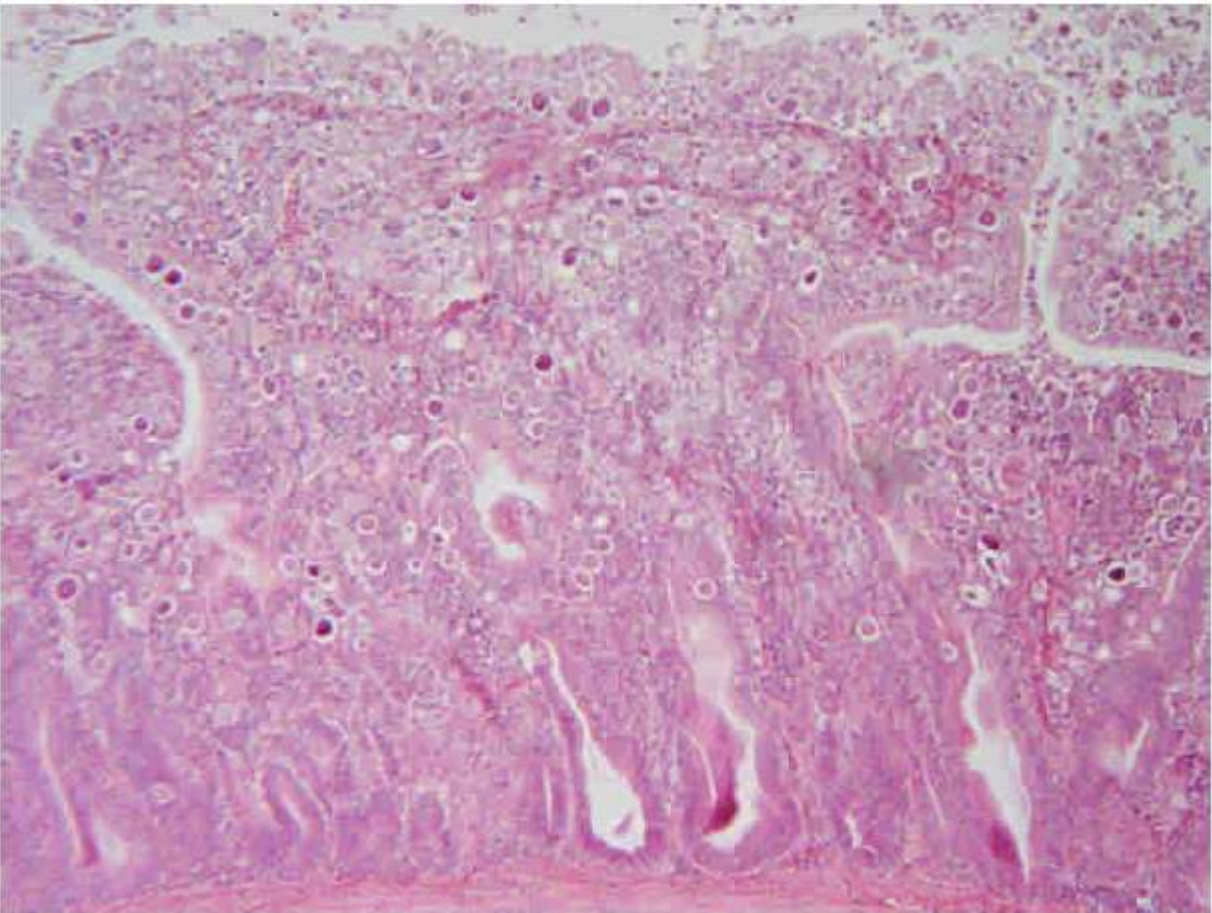
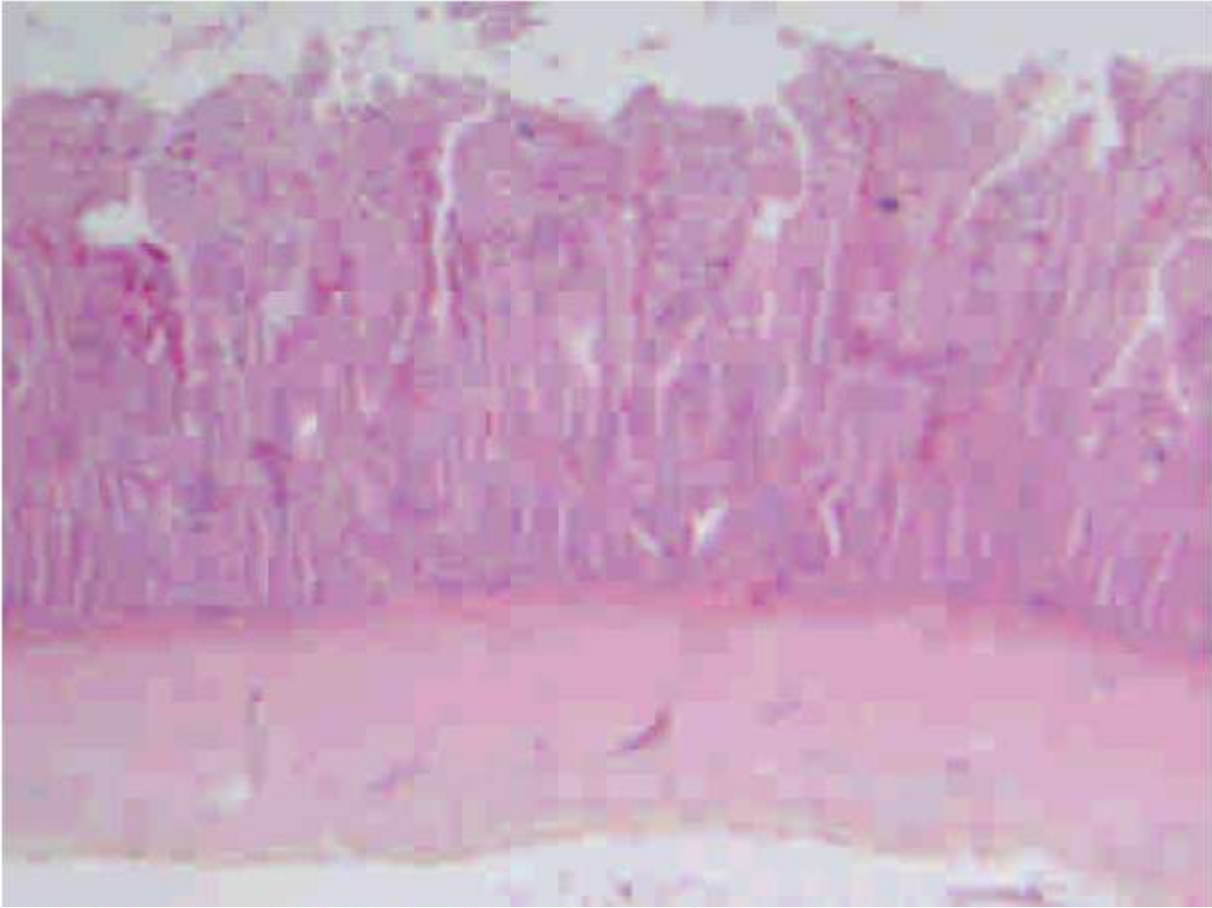


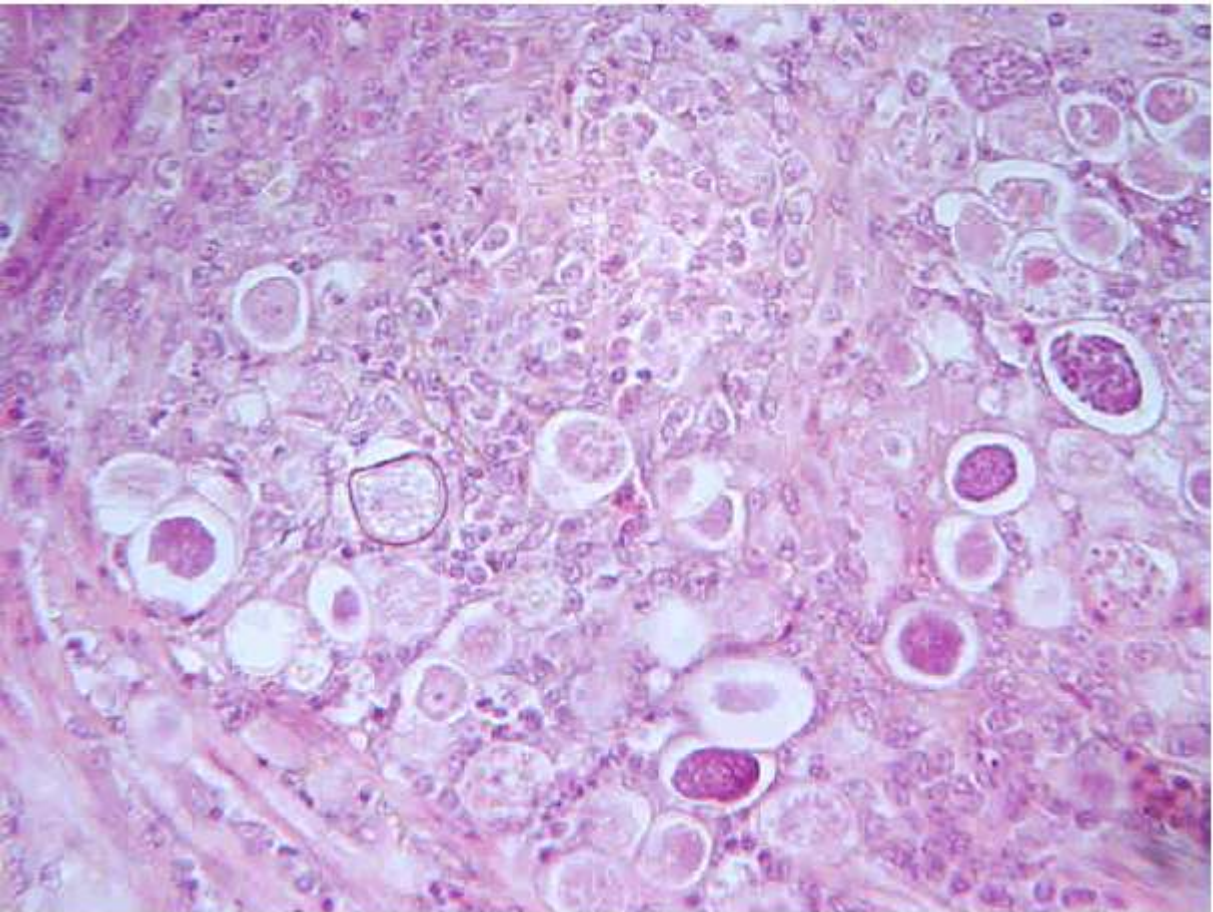
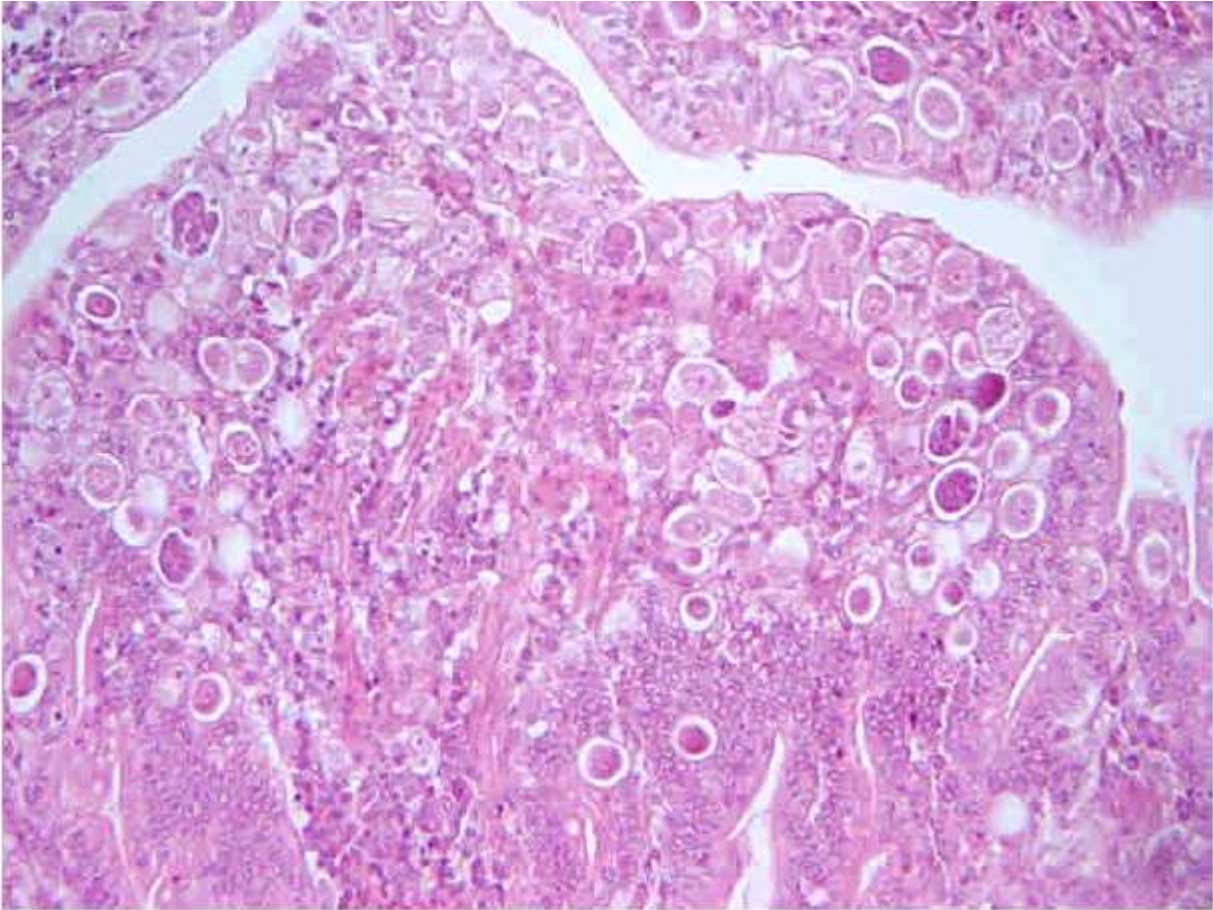
Marie Curie Training Courses

Summer School 2007 – Avian P1

P1 : Tissue from a chicken

- Morphologic diagnosis/es
- Etiologic diagnosis/es





P1 : Tissue from a chicken

- Morphologic diagnosis/es
Small intestine, enteritis, chronic, diffuse, lymphocytic, with superficial epithelial erosion, crypt hyperplasia and massive intra-epithelial enterocytic infestation by coccidians protozoans (*Eimeria* sp.)
- Etiologic diagnosis/es
Intestinal coccidiosis