



ECVP/ESVP Summer School in Veterinary Pathology

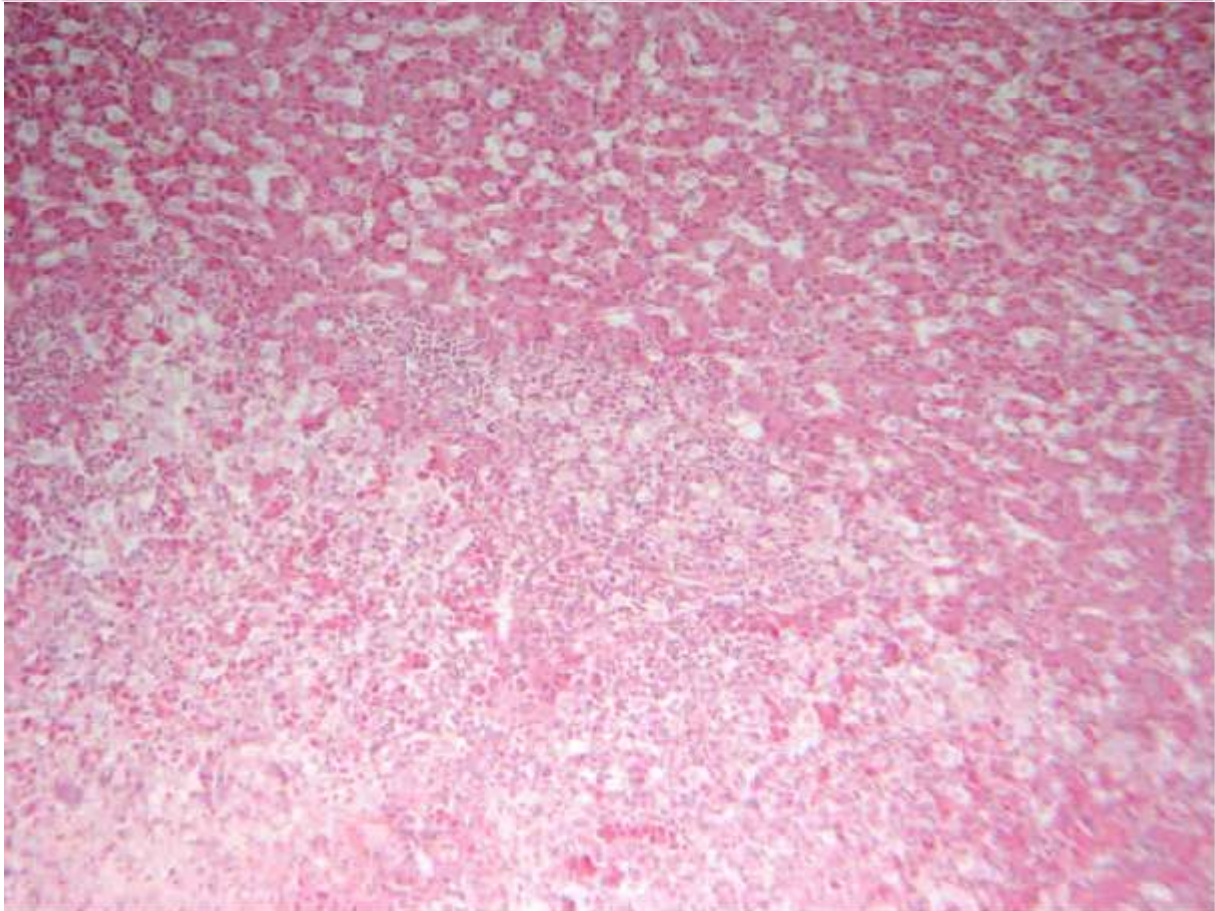
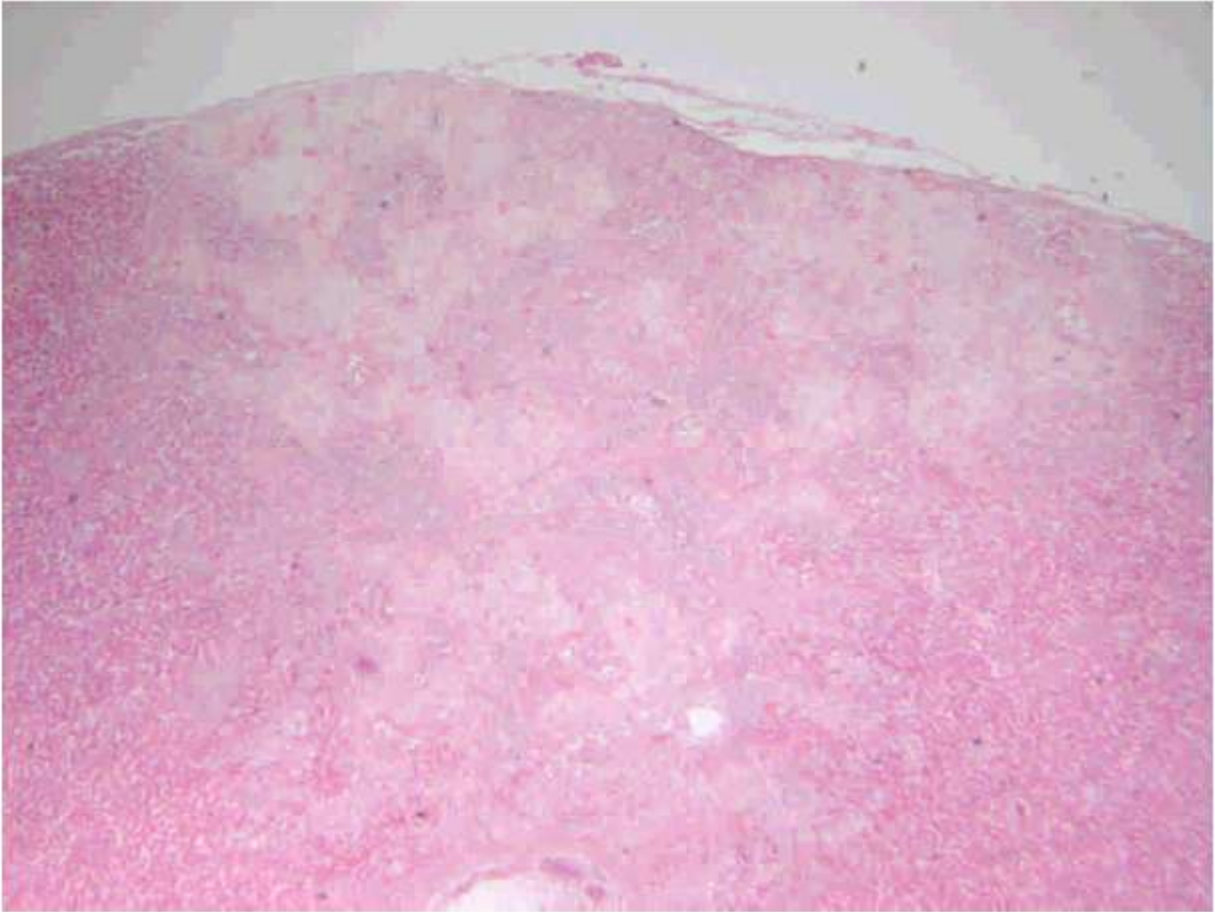

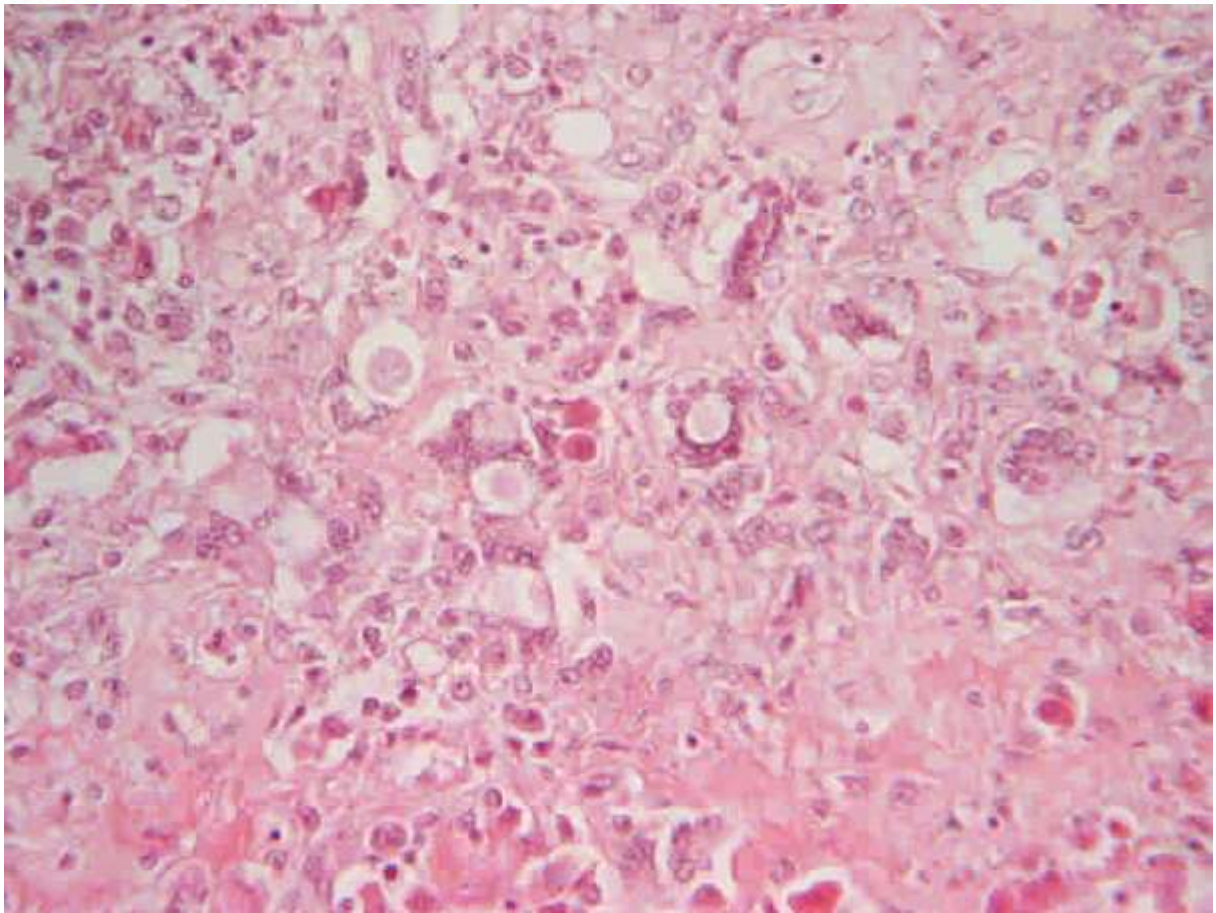
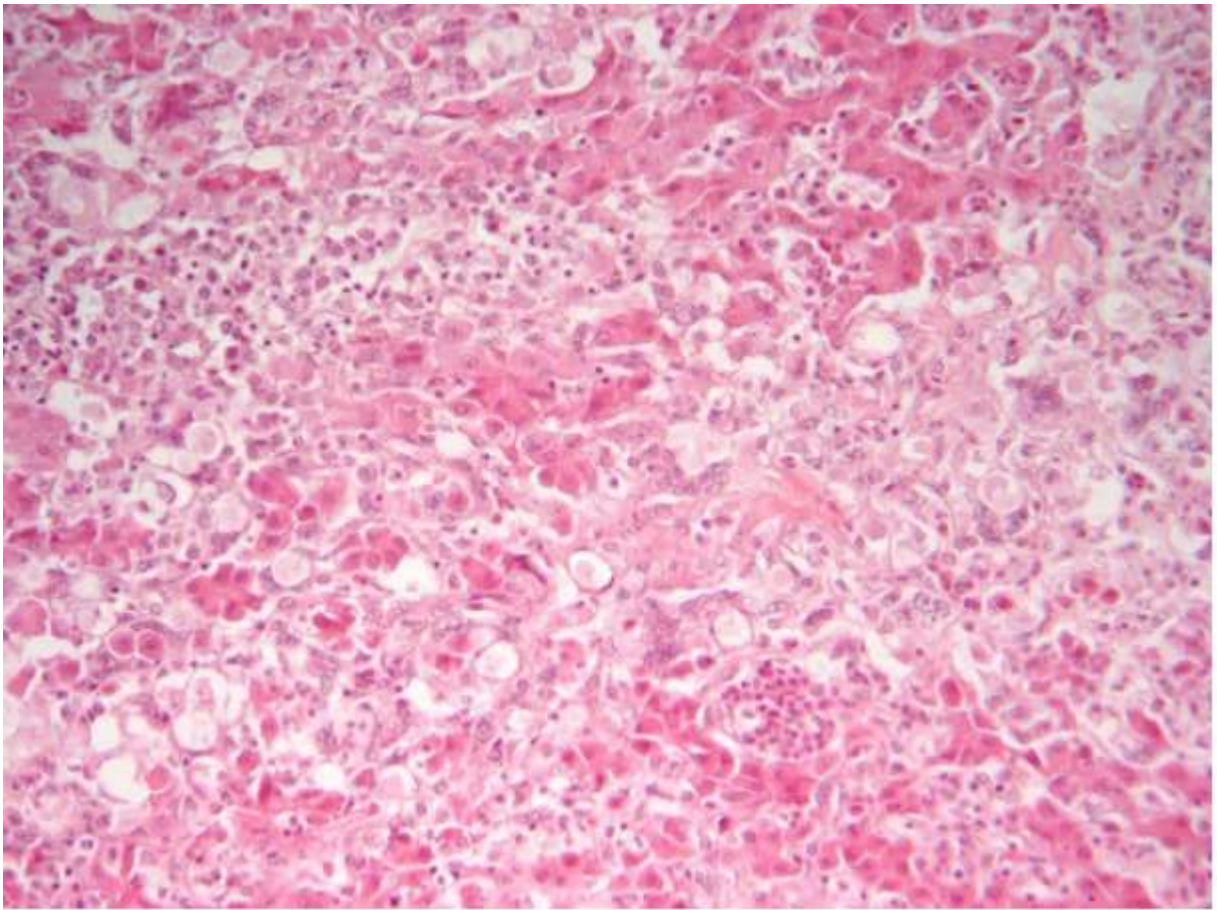
Marie Curie Training Courses

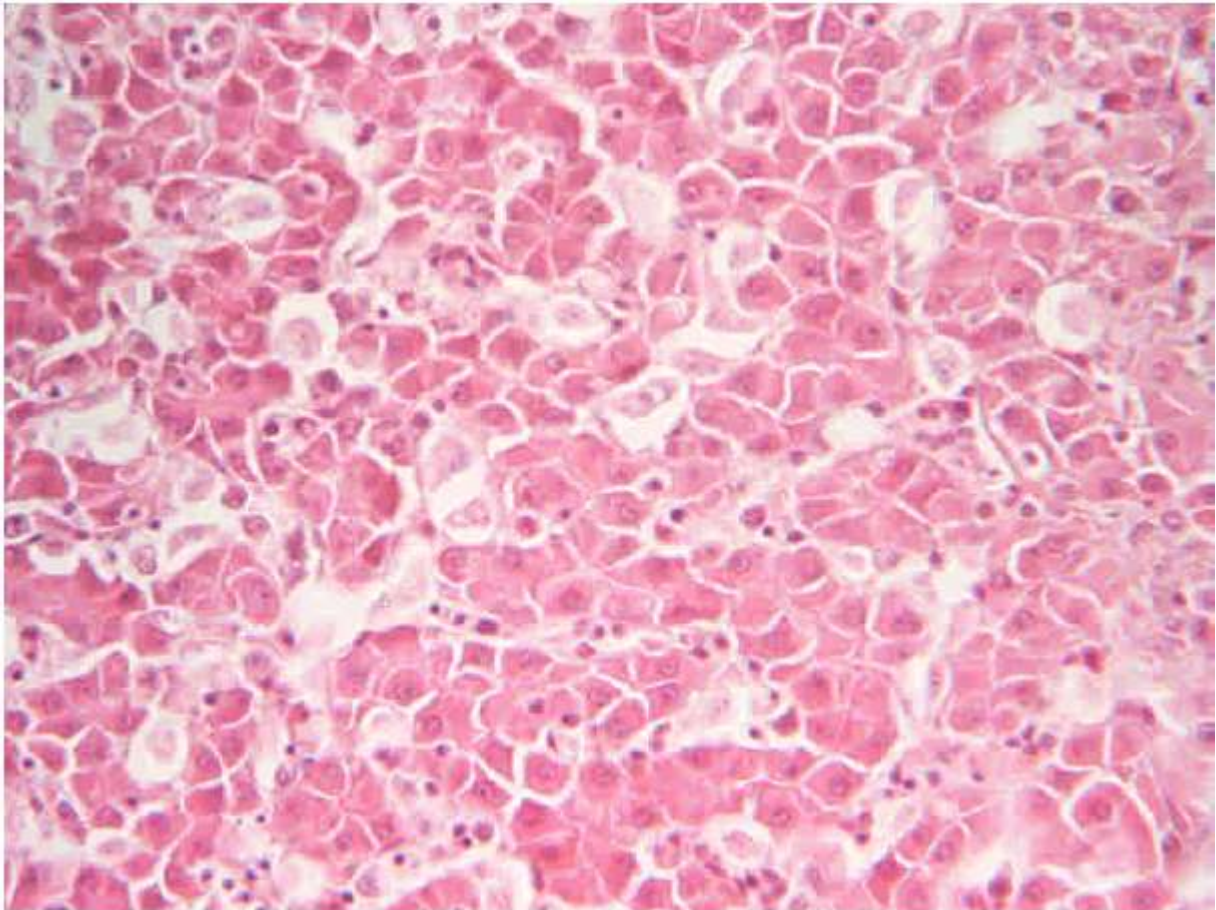
Summer School 2007 – Avian P3

P3 : Tissue from a chicken

- Morphologic diagnosis/es
- Etiologic diagnosis/es







P3 : Tissue from a chicken

- Morphologic diagnosis/es
Liver, hepatitis, subacute, multifocal to coalescing, necrotizing and macrophagic, associated with intralésional protozoans, morphology consistent with trophozoites of *Histomonas meleagridis*)
- Etiologic diagnosis/es
Hepatic histomonosis