



ECVP/ESVP Summer School in Veterinary Pathology

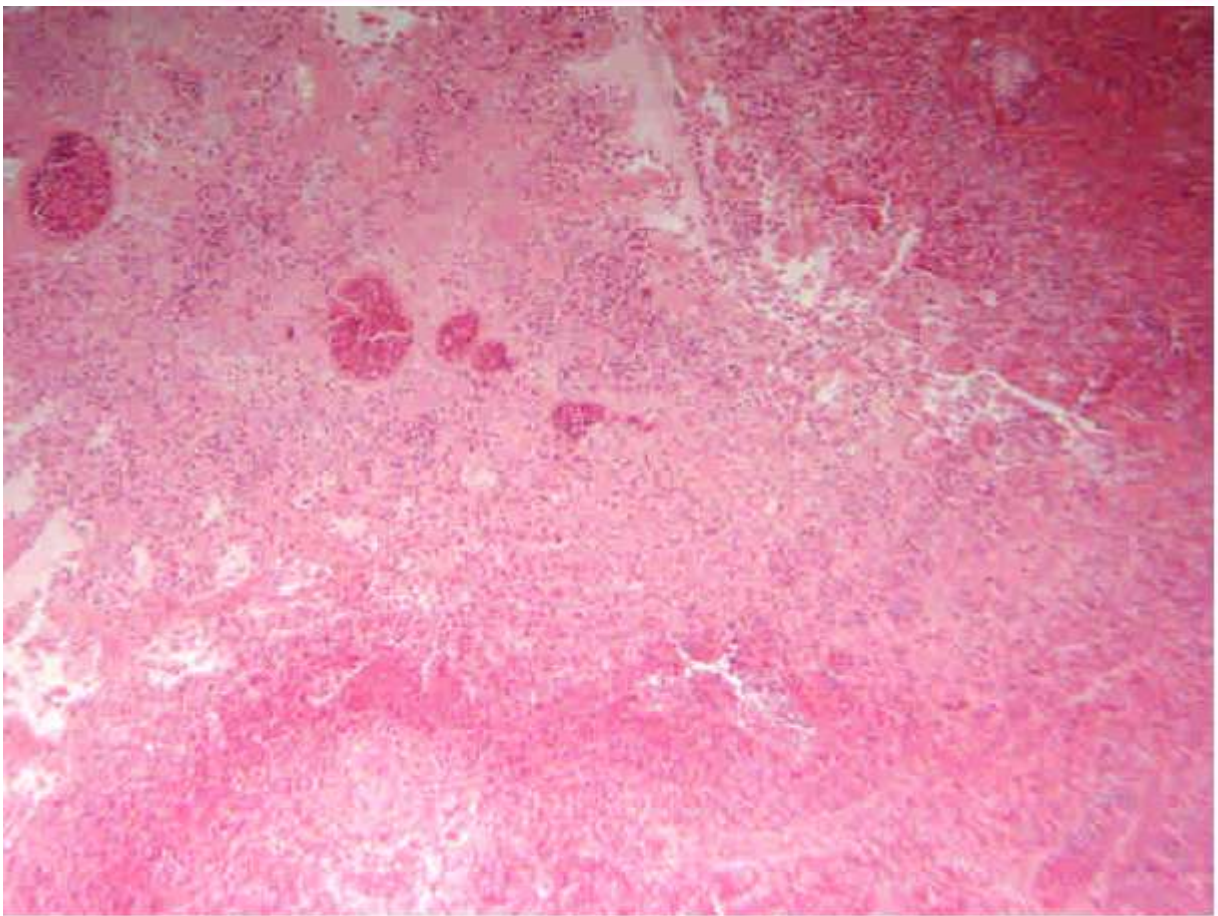
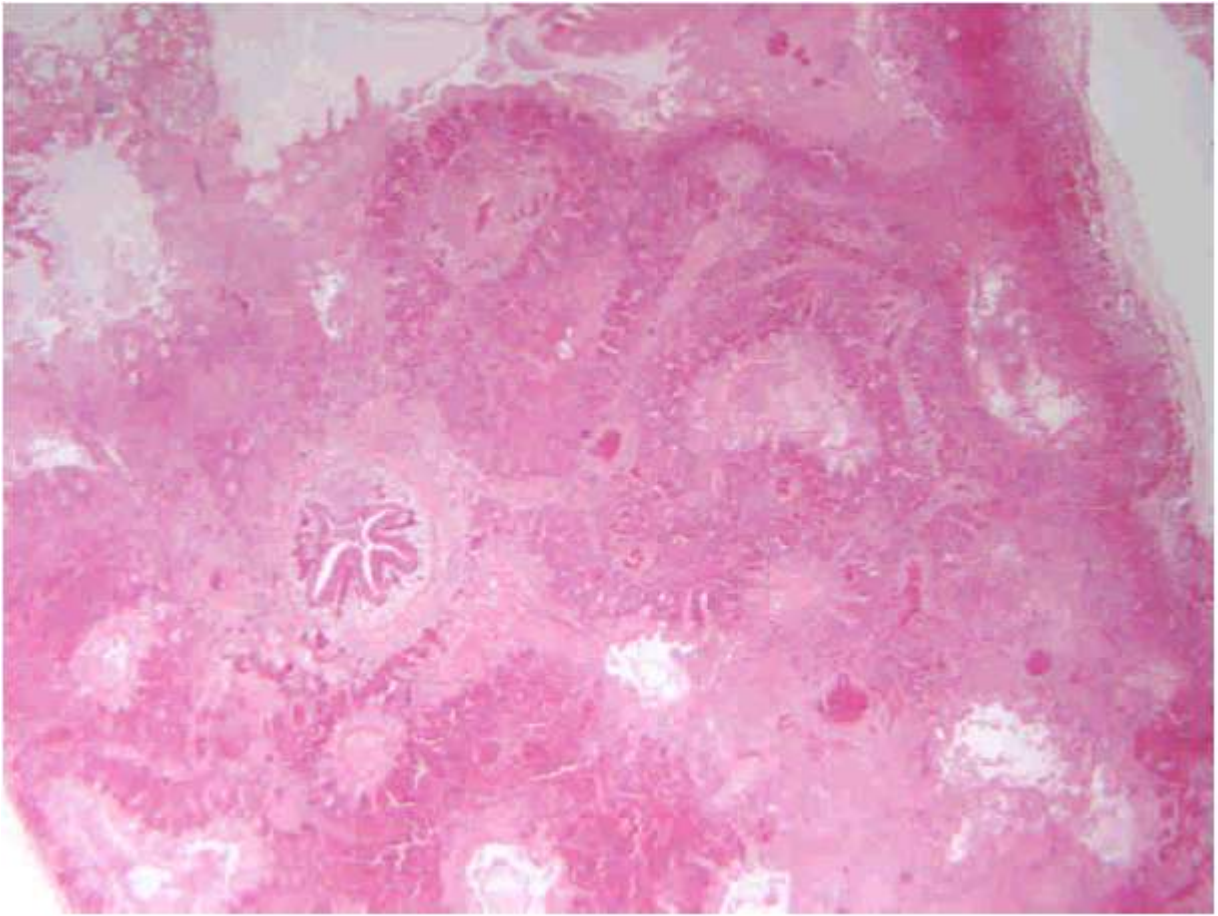


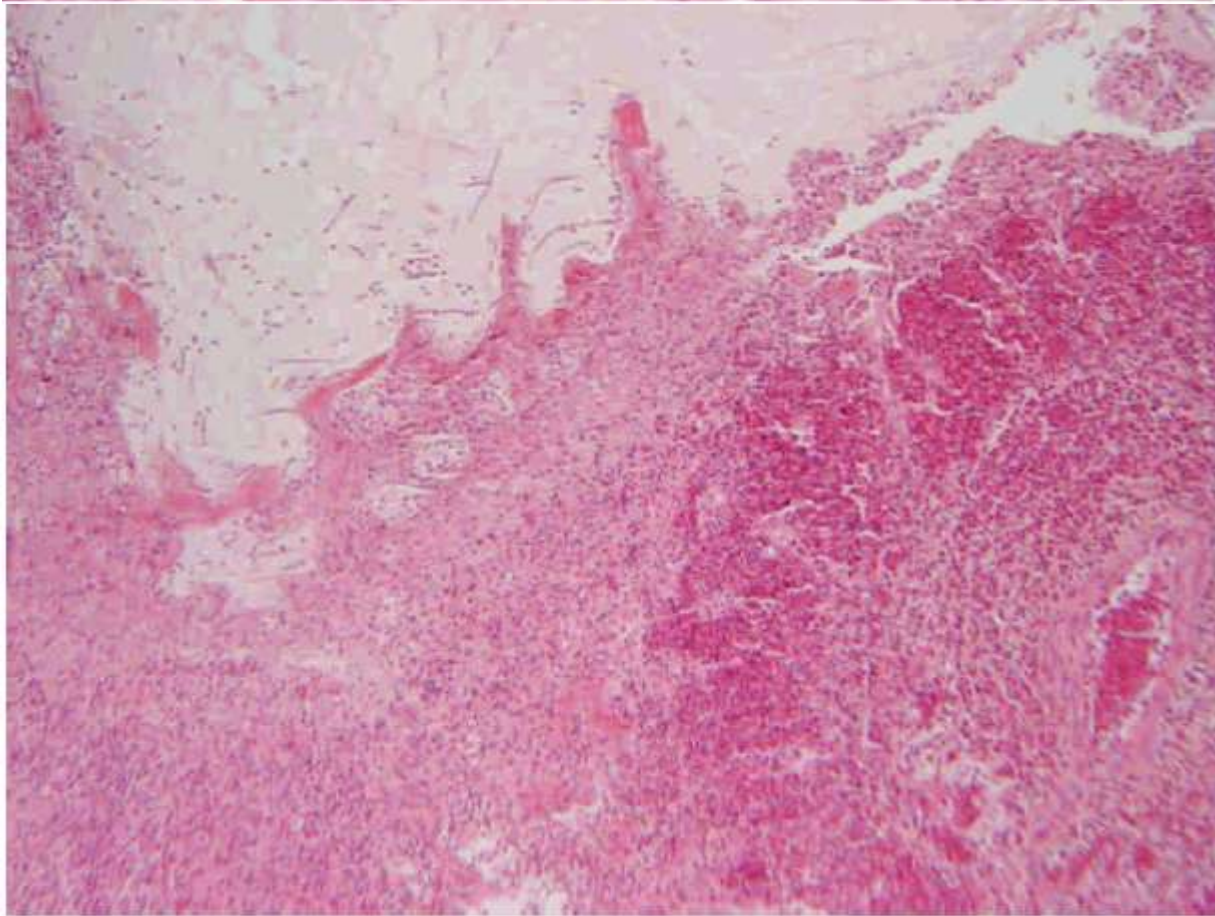
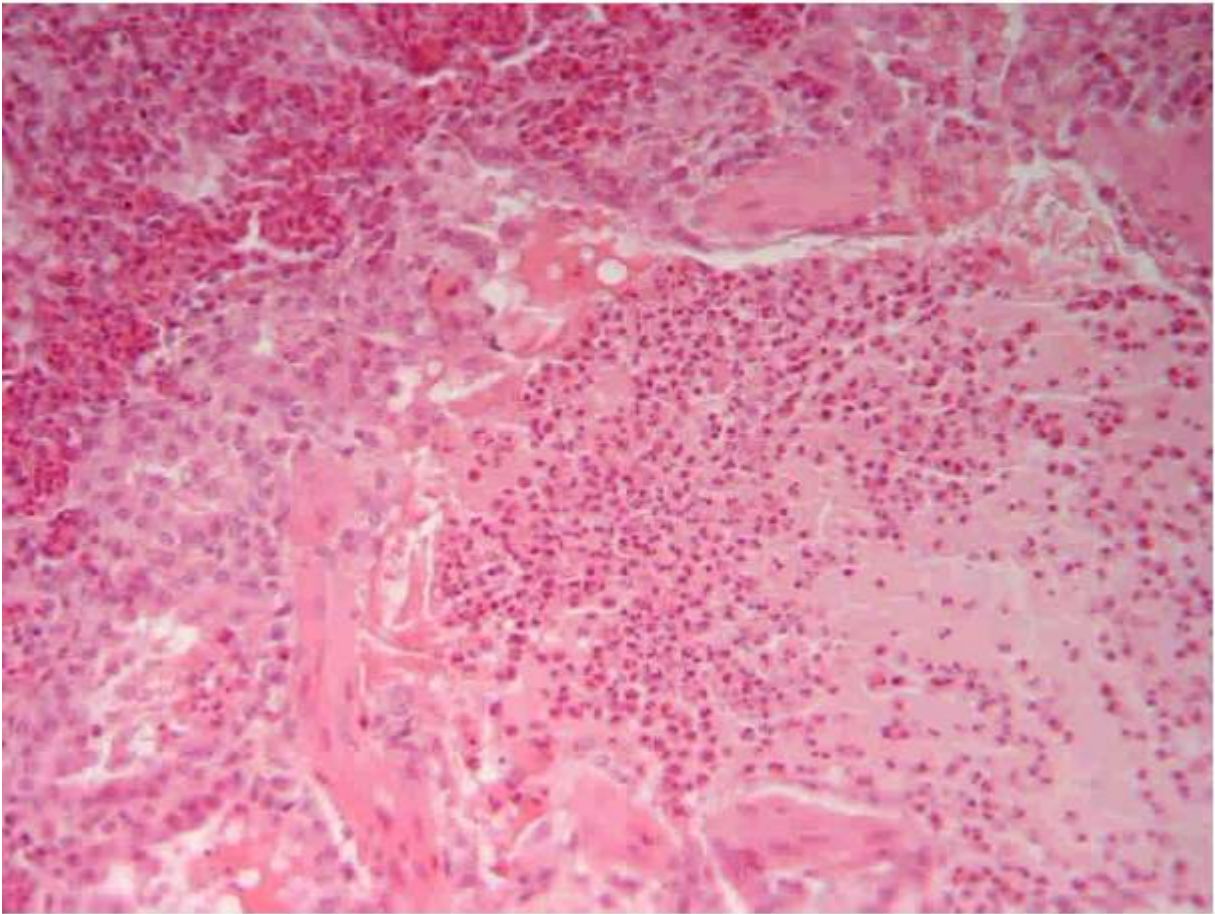
Marie Curie Training Courses

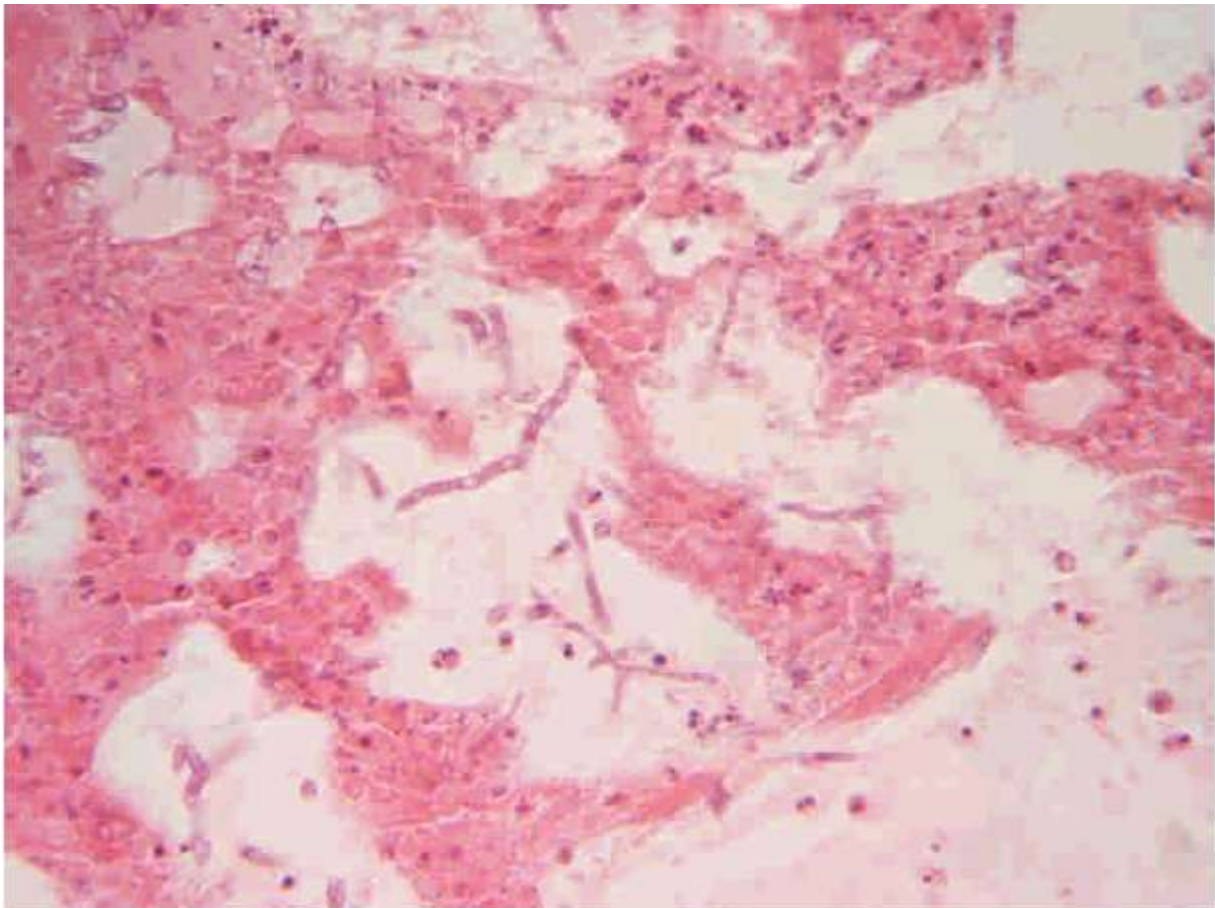
Summer School 2007 – Avian P4

P4 : Tissue from a chicken

- Morphologic diagnosis/es
- Etiology/ies







P4 : Tissue from a chicken

- Morphologic diagnosis/es
Lung, pneumonia, acute, edematous and heterophilic, with focal infarction associated with intralésional spores and hyphae, septate and branched, morphology consistent with *Aspergillus* sp.
- Etiology/ies
Aspergillus fumigatus