



# ECVP/ESVP Summer School in Veterinary Pathology

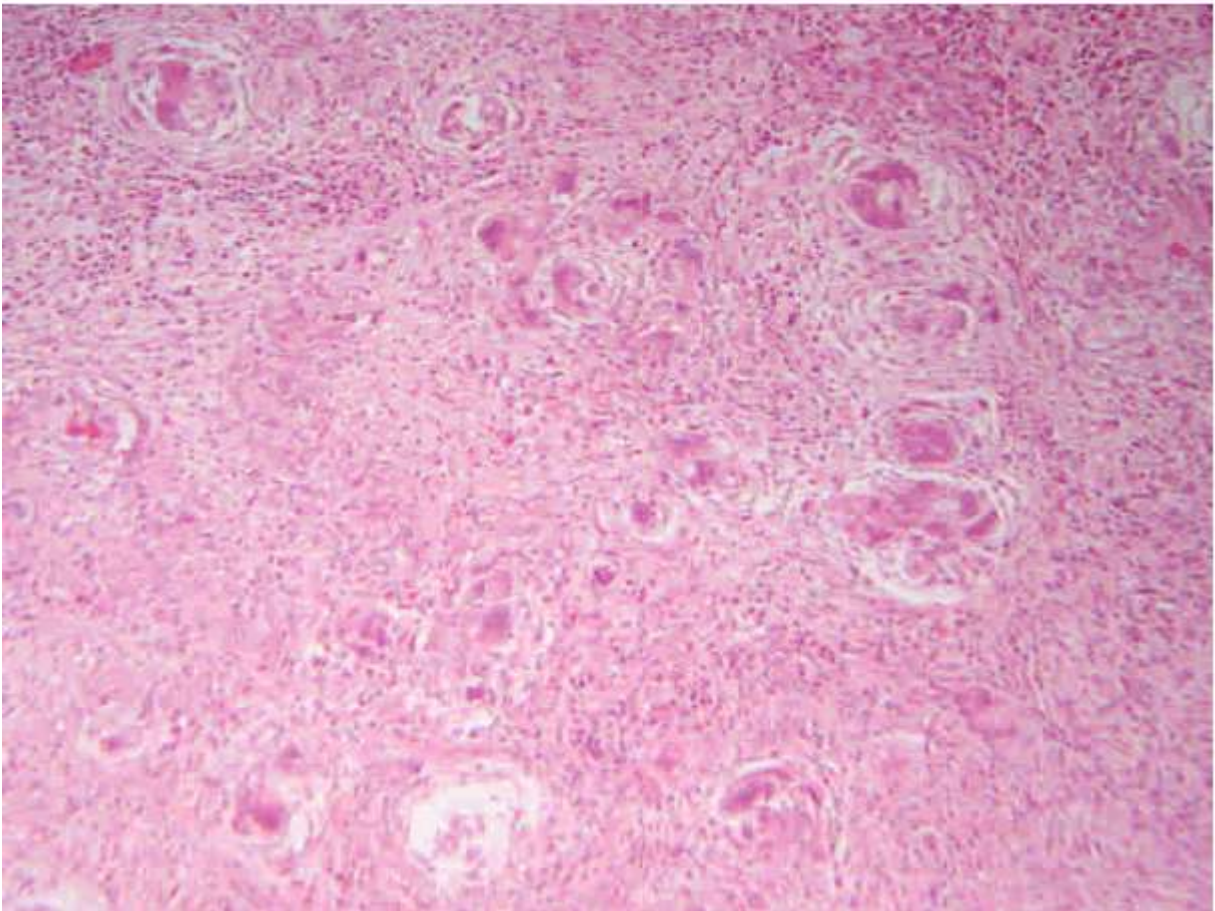
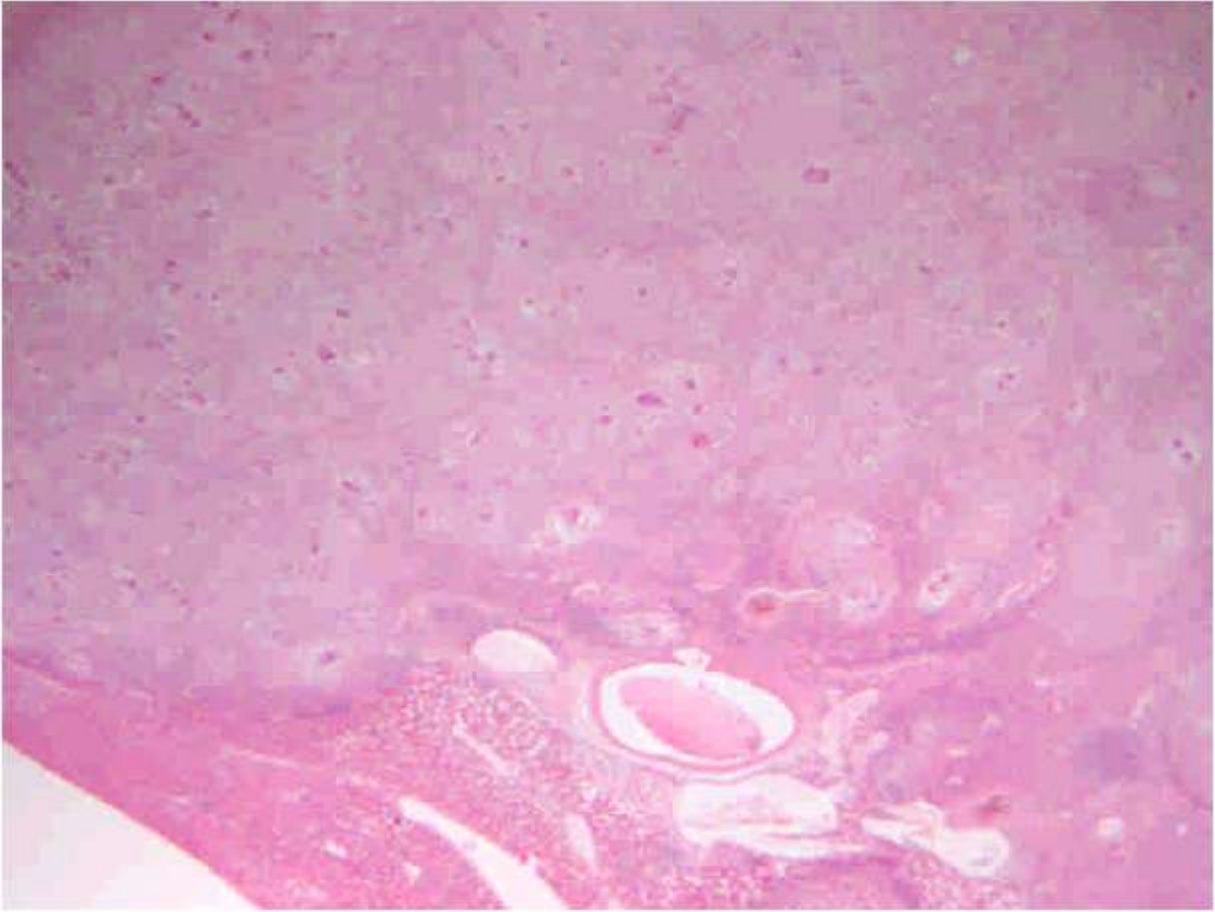


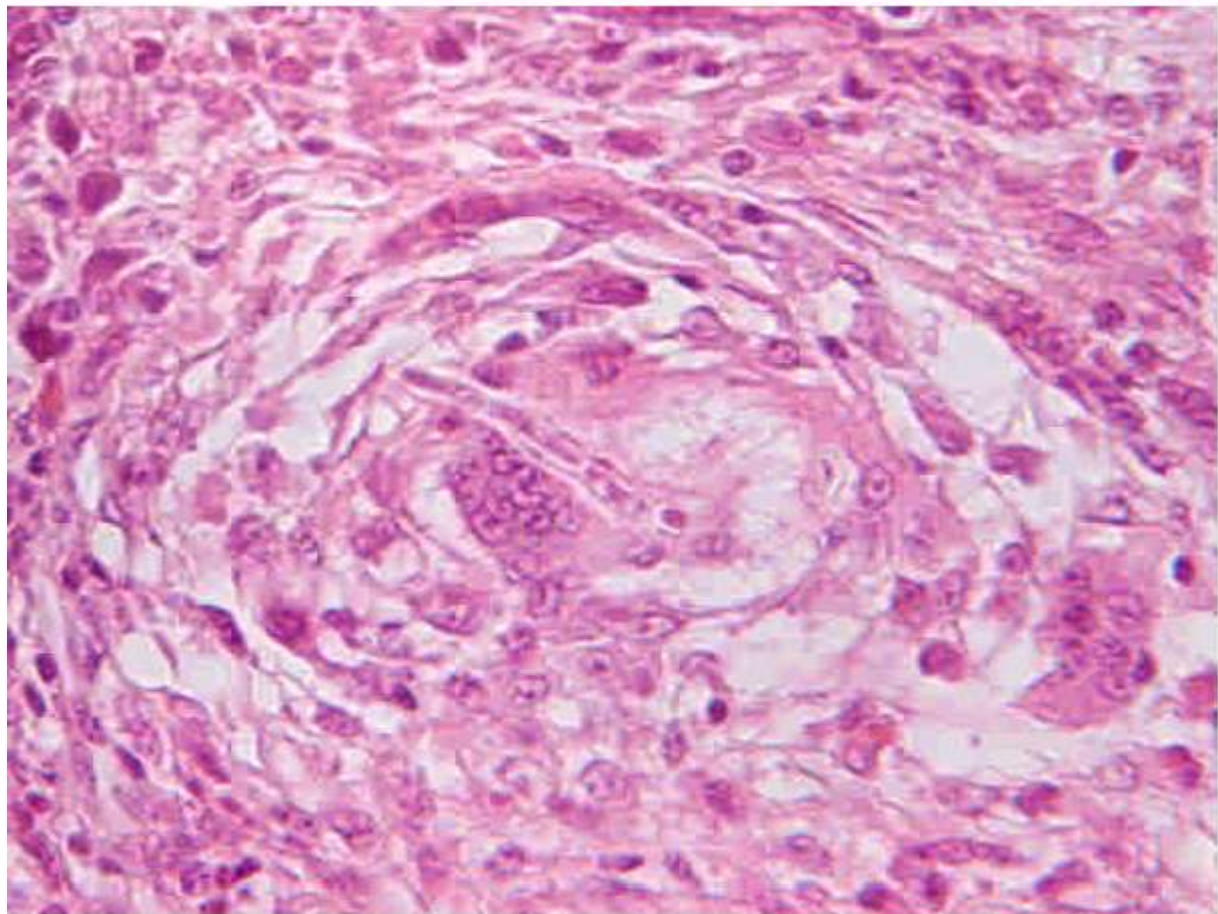
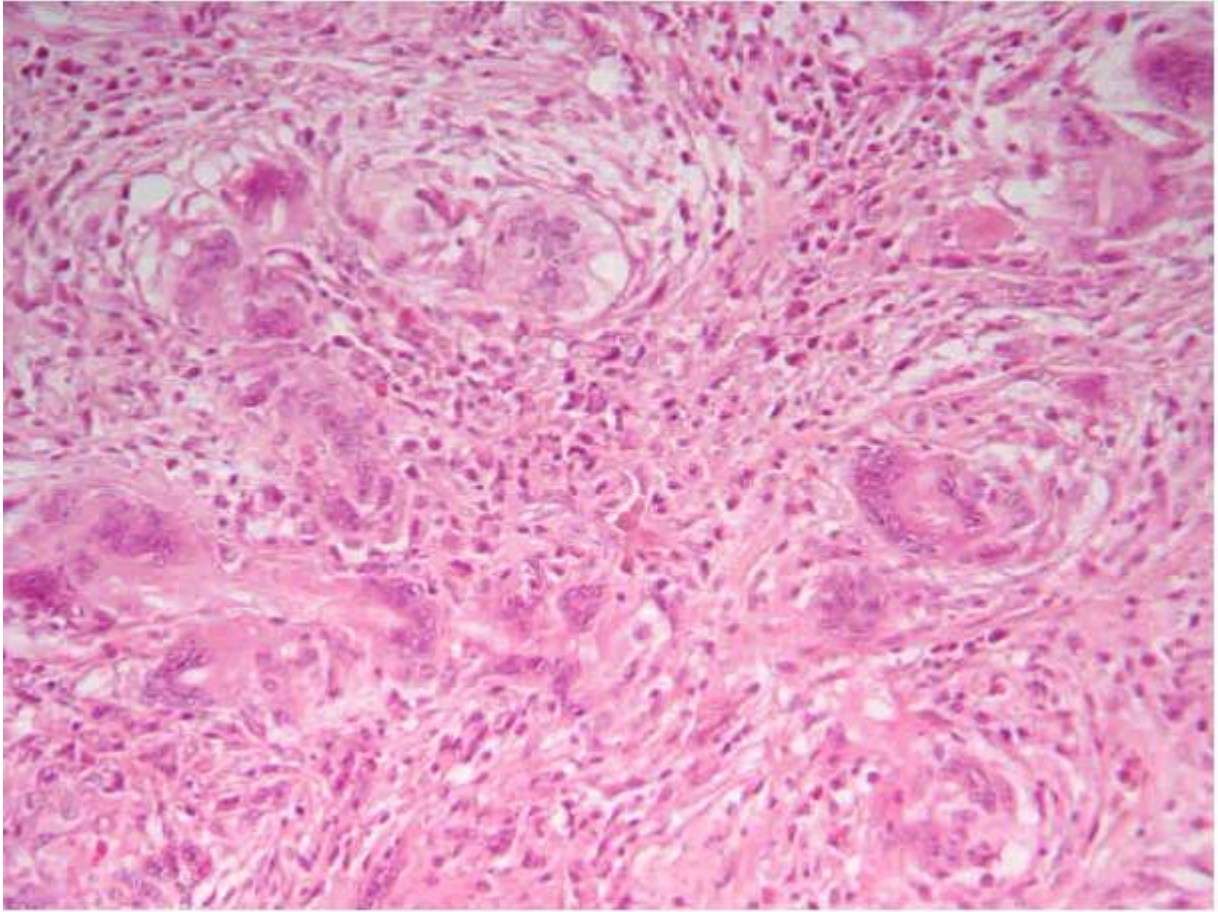
**Marie Curie Training Courses**

Summer School 2007 – Avian P5

## P5 : Tissue from a duck

- Morphologic diagnosis/es
- Etiologic diagnosis/es





## P5 : Tissue from a duck

- Morphologic diagnosis/es  
Liver, hepatitis, chronic, granulomatous and fibrosing, associated with intralesional spores and hyphae, septate and branched, morphology consistent with *Aspergillus* sp.
- Etiologic diagnosis/es  
Hepatic aspergillosis