



ECVP/ESVP Summer School in Veterinary Pathology



Marie Curie Training Courses

Summer School 2007 – Avian T1/T2/T3/T4

MAREK'S DISEASE in CHICKEN

- **Histological lesions: Practical**

- ☐ **Various tissues from different MD affected chickens**

- ⌘ **T1: Nerves**

- ◆ Different samples of nerves from the same bird.
 - ◆ Association of type A and Type B lesions depending on the nerve.

- ⌘ **T2: Spleen**

- ◆ Diffuse, severe, generalized ± monomorphic neoplastic infiltrate with important splenomegally.
 - ◆ Ischemic necrosis of neoplastic cells in the centre of the tumour with cell retraction and pyknotic nuclei.

- ⌘ **T3: Liver +Proventriculus**

- ◆ **Liver:** Multifocal to coalescent severe neoplastic infiltrate by pleomorphic lymphoid cells. Numerous mitotic figures and pyknotic cells.
 - ◆ **Proventriculus:** Massive, diffuse, neoplastic infiltrate of the *lamina propria* of the mucosa without epithelial ulceration. Moderate, multifocal infiltrate in the glandular lobules of the submucosa, mainly located around the central cavity of the glands.

- ⌘ **T4: Skin**

- ◆ Severe, diffuse, neoplastic infiltration of the dermis and subcutis in contact with the epidermis focally ulcerated and extending to the skin muscles. Pseudo-follicles structures can be identified.

AVIAN TUMOURS

- **Classification**

- ☐ **Viral induced tumours**

- ⌘ **Herpesvirus: Marek's Disease**

- ⌘ **Retrovirus**

- ◆ **ALV/RSV group**

- ↳ **Lymphoid leukosis: Lymphomatosis**
 - ↳ **Erythroblastosis and Myeloblastosis/Myelocytomatosis**
 - ↳ **Sarcomas and other connective tissues tumours**
 - ↳ **Nephroblastomas, Haemangiomas, Haemangiosarcomas, hepatocarcinomas, pancreatic adenocarcinomas, ovarian tumours**
 - ↳ **Osteopetrosis**

- ◆ **REV group**

- ↳ Spontaneous lymphoid neoplasms in turkeys ?

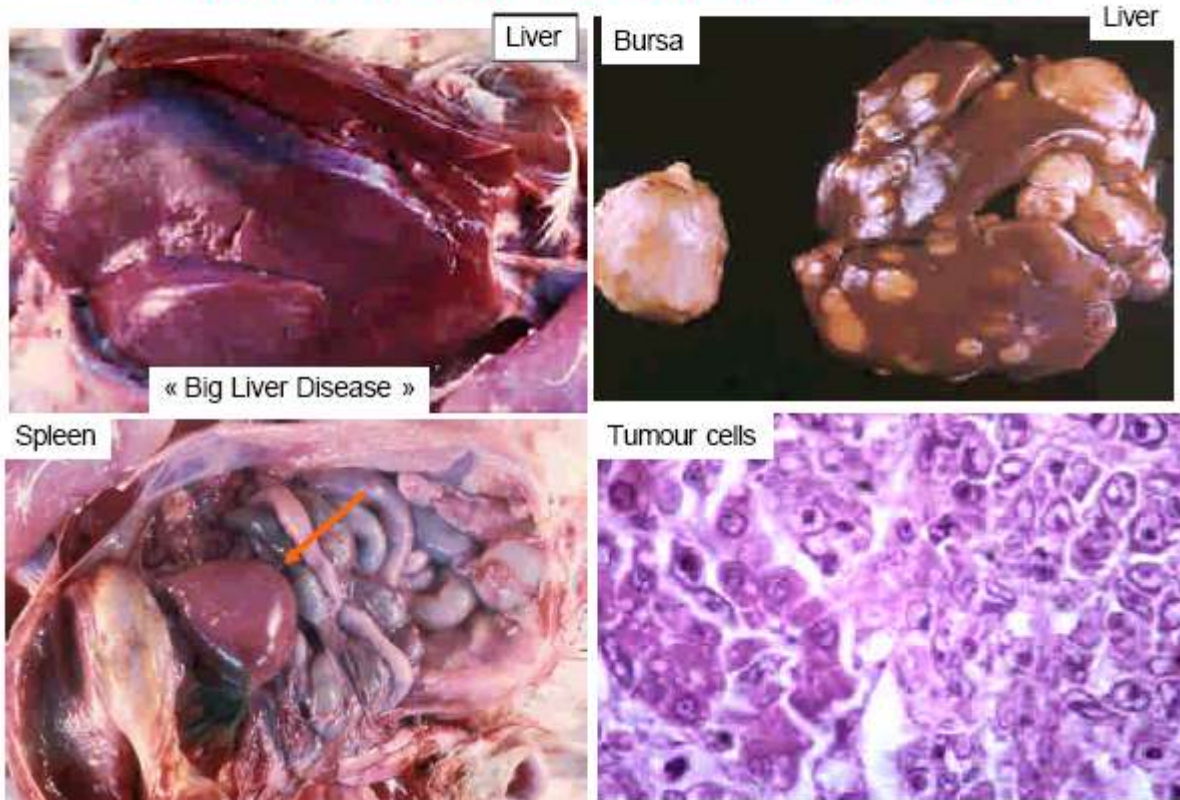
- ☐ **Tumours of unknown aetiology**

- ⌘ **Benign and malignant neoplasms of various tissues**

LYMPHOID LEUKOSIS in CHICKEN (LYMPHOMATOSIS)

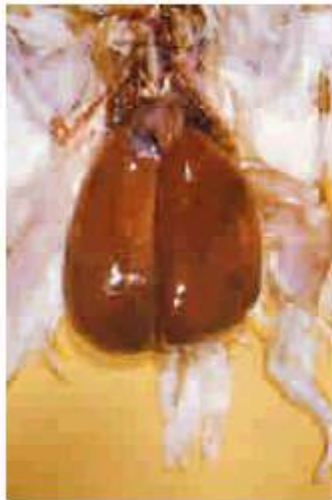- Retrovirus from ALV/RSV (Avian Leukemia, Rous Sarcoma Viruses) group
- Genetic selection eradicated the retroviruses from commercial strains of poultry
- Lymphomatosis is not an economical problem today in poultry industry
- Rare, sporadic cases in non selected ornamental strains of chicken

LYMPHOID LEUKOSIS in CHICKEN

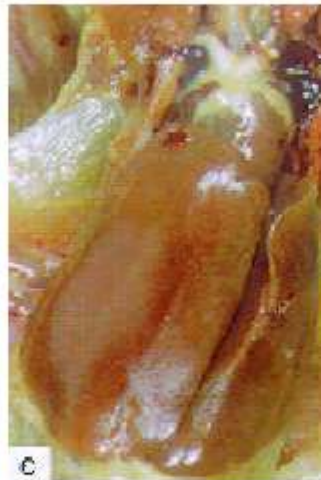

ERYTHROBLASTOSIS and MYELOBLASTOSIS

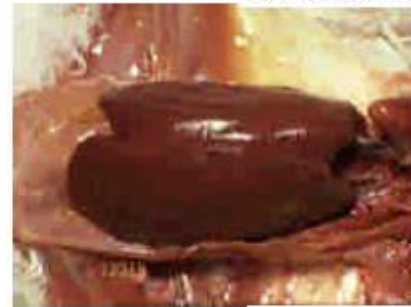Liver: Severe diffuse tumoral infiltration with important Hepatomegaly (+ Leukemia)



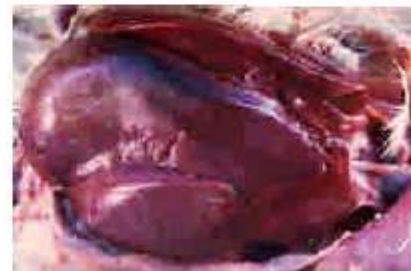Erythroblastosis
Enlarged cherry red liver



Myeloblastosis
Enlarged grey red liver



Marek's Disease



Lymphomatosis

Diffuse forms of hematopoietic neoplasms affecting the liver grossly indistinguishable

↔ HISTOLOGY

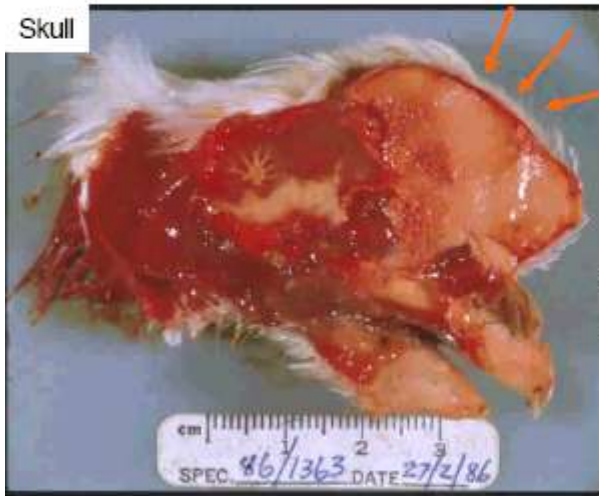MYELOCYTOMATOSIS IN CHICKEN

- Frequency dramatically increased in the early 90ties in the broiler breeders
- ALV **subgroup J** (typical chronic non transforming retrovirus devoids of oncogen)
- New ALV subgroup (recombinant from endogen and exogen viral genomes)
- Specific tropism for heterophils myeloid cells inducing **myelocytomatosis**
- Tumours located in **bones** (sternum, ribs, skull, pelvis...) **muscles**, various organs (liver, spleen, kidney...)
- Rarely, ALV-J may also induce spontaneously other types of tumours as : Hemangiomas, Nephroblastomas, Sarcomas, Erythroblastosis....
- ALV-J **almost eliminated today** by genetic selection

MYELOCYTOMATOSIS IN CHICKEN

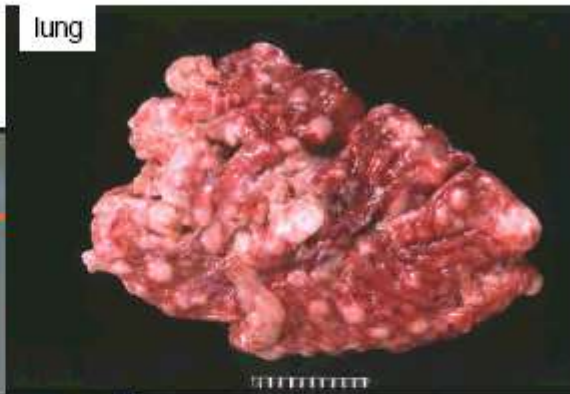- Gross lesions

Skull



Diffuse or multinodular infiltration often coexists in liver, spleen, kidney...

lung



Heart

