

## Marie Curie Training Courses

Summer School 2007 – Avian T5/T6/T7/T8

## MYELOCYTOMATOSIS IN CHICKEN

- **Histological lesions: Practical**
  - ☑ **Various Tissues from a 22 weeks old laying Hen**

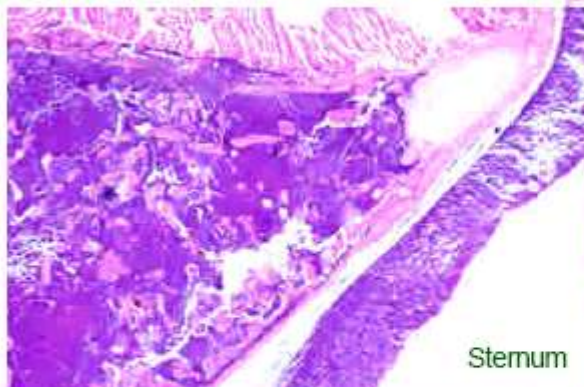
⌘ T5: Bone (Sternum)

⌘ T6: Bone (Pelvis)

⌘ T7: Liver + Kidney

## MYELOCYTOMATOSIS IN CHICKEN

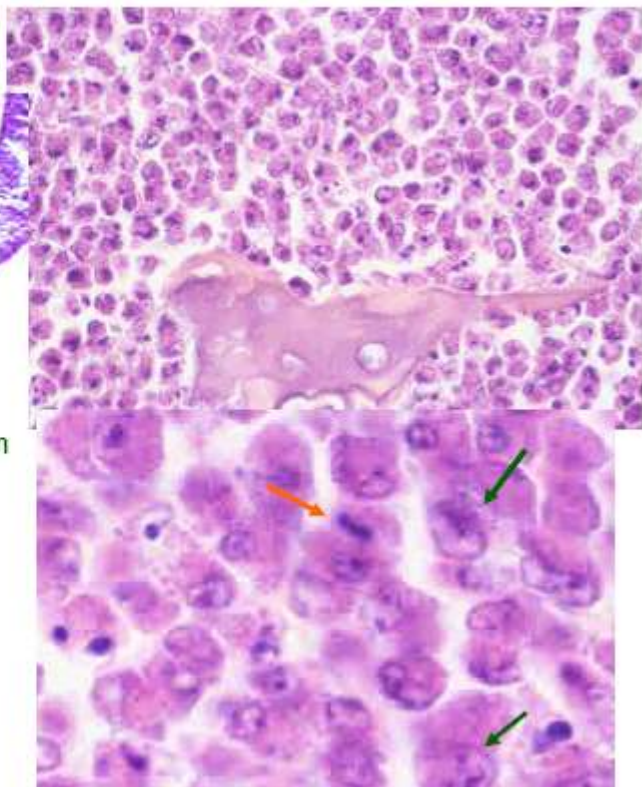
- **Histological lesions: Bones**



Massive, diffuse tumoral infiltration of bone marrow extending to periosteum, periosseous muscle and connective tissue

Monomorphic tumoral population of granular heterophilic cells

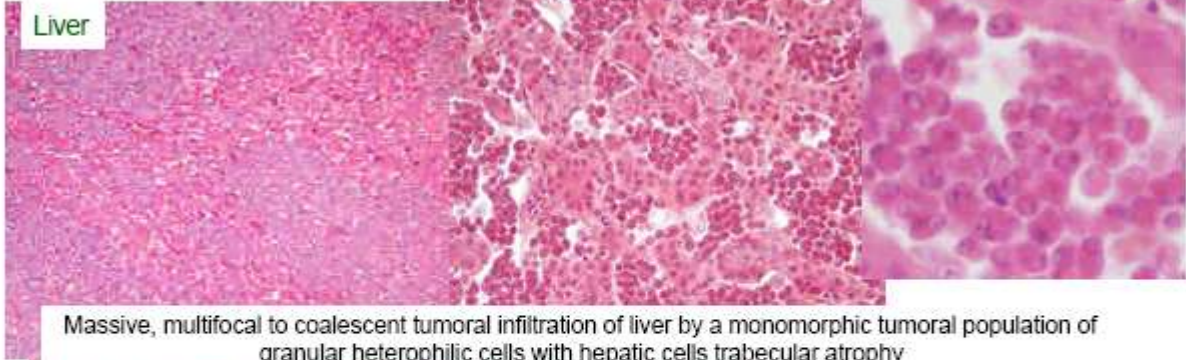Tumoral myelocytes with anisocaryosis and mitotic figures



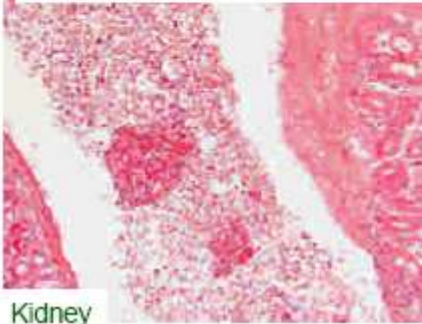
# MYELOCYTOMATOSIS IN CHICKEN

- Histological lesions : Organs

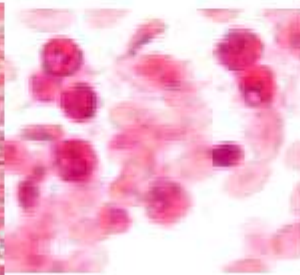
Liver



Massive, multifocal to coalescent tumoral infiltration of liver by a monomorphic tumoral population of granular heterophilic cells with hepatic cells trabecular atrophy

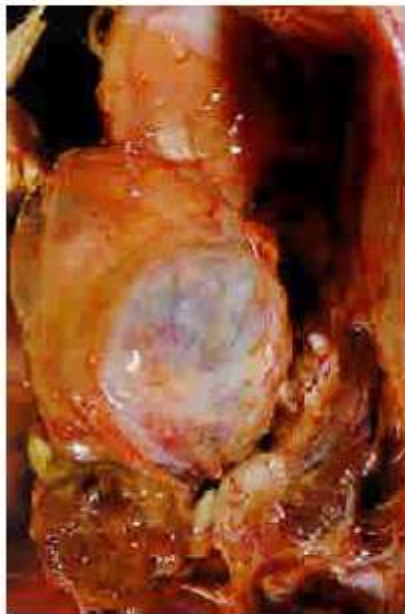

Kidney

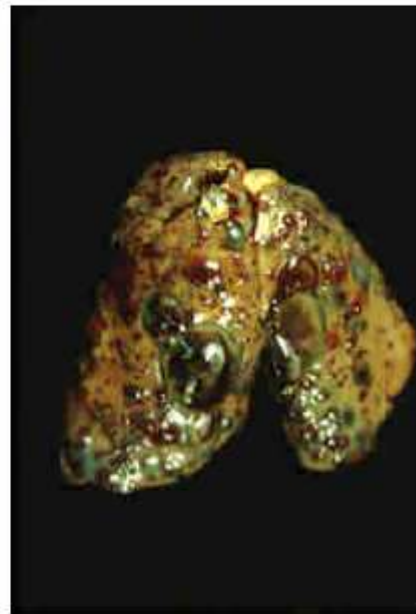


No interstitial tumoral infiltration.  
Presence of circulating tumoral cells  
in large extrarenal vessels:  
**Leukemia**

## NON HEMATOPOIETIC RETROVIRUS INDUCED TUMOURS



Nephroblastoma

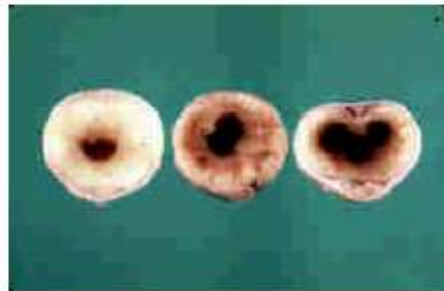
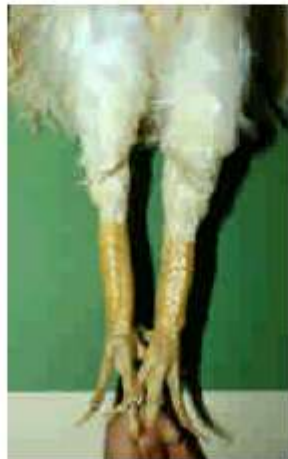
Hemangiosarcoma



# OSTEOPETROSIS

- Non neoplastic proliferation of bone tissue associated with production of ALV by osteoblasts
- Bilateral symetric hypertrophy of the tibia and tarsometatarsus diaphysis with regular fusiform enlargement and obliteration of bone marrow cavity by newly formed spongy bone
- Lymphoid leukosis often occurs



# AVIAN TUMOURS

- **Classification**

- ☒ **Viral induced tumours**

- ↪ Herpesvirus: Marek's Disease

- ↪ Retrovirus

- ◆ ALV/RSV group

- ↪ Lymphoid leukosis: Lymphomatosis

- ↪ Erythroblastosis and Myeloblastosis/Myelocytomatosis

- ↪ Sarcomas and other connective tissues tumours

- ↪ Nephroblastomas, hemangiomas, hepatocarcinomas...

- ↪ Osteopetrosis

- ◆ REV group

- ↪ Spontaneous lymphoid neoplasms in turkeys ?

- ☒ **Tumours of unknown aetiology**

- ↪ Benign and malignant neoplasms of various tissues

# Tumours of unknown aetiology

- Skin tumours

- ☒ **Dermal Squamous Cell Carcinoma: Keratoacanthoma in chicken**

- ↳ Young broiler chickens

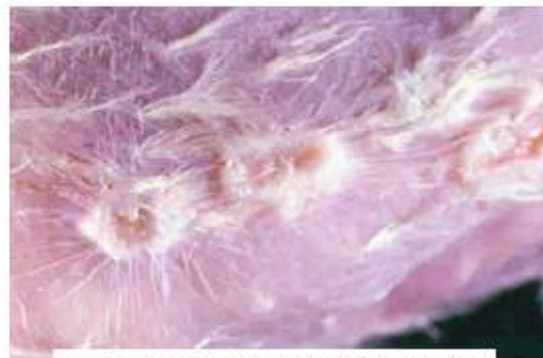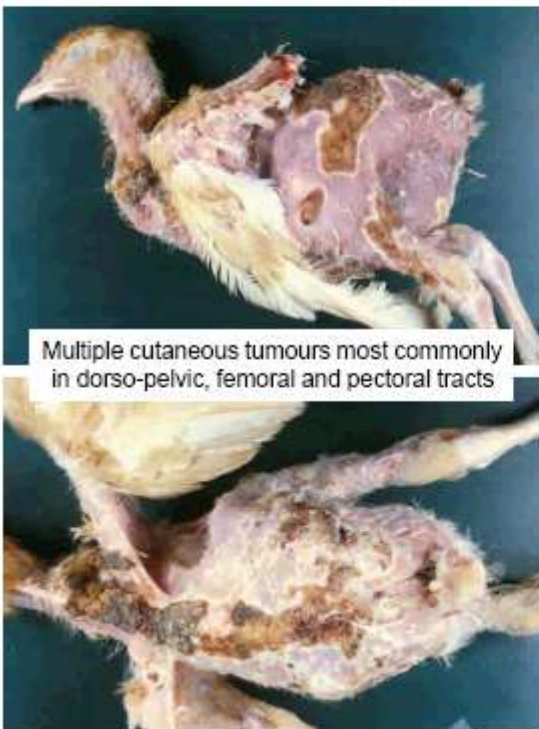
- ↳ Most of the time identified at slaughterhouse on dressed carcasses (1p1000 or more in some individual flocks)

# Tumours of unknown aetiology

- Skin tumours

- ☒ **Dermal Squamous Cell Carcinoma: Keratoacanthoma in chicken**

- ↳ Gross



## Tumours of unknown aetiology

### •Skin tumours

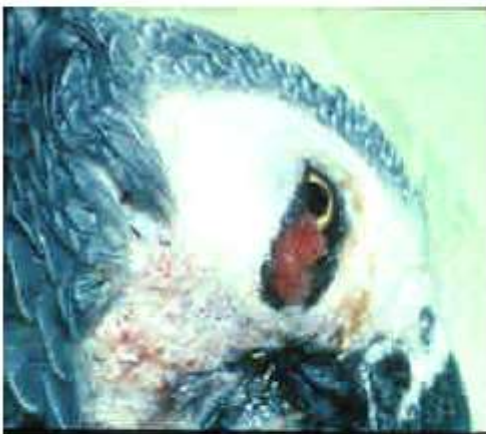#### ☒ Dermal Squamous Cell Carcinoma: Keratoacanthoma in chicken

- ☞ Young broiler chickens
- ☞ Most of the time identified at slaughterhouse on dressed carcasses (1p1000 or more in some individual flocks)
- ☞ **Gross**
- ☞ No metastasis, may regress spontaneously
- ☞ **Histo** : Well differentiated keratinized squamous cell Carcinoma : kerato-acanthoma
- ☞ **Aetiology** ?
  - ◆ Avian pox genoma identified in tumour cell nuclei using PCR

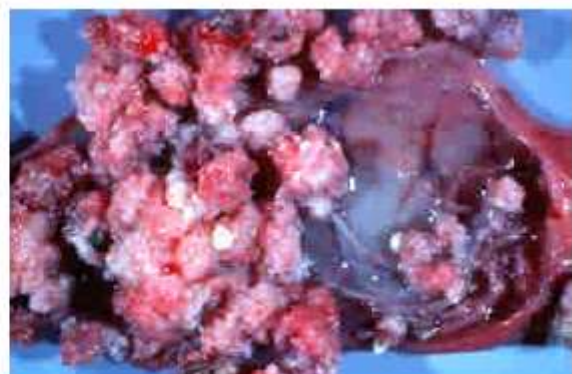
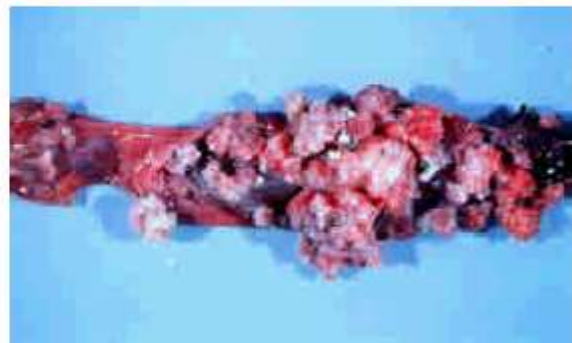
## Tumours of unknown aetiology

### • Papillomas: Papillomatosis

- ☒ Psittacines ++
- ☒ Skin
- ☒ Mouth, Oesophagus, Crop



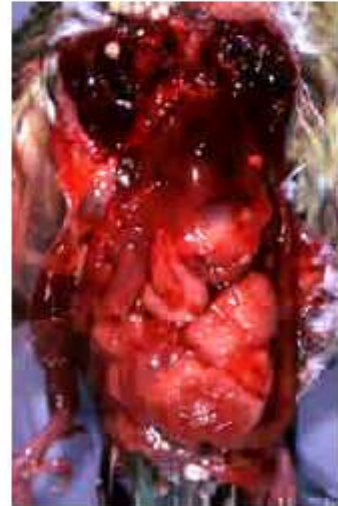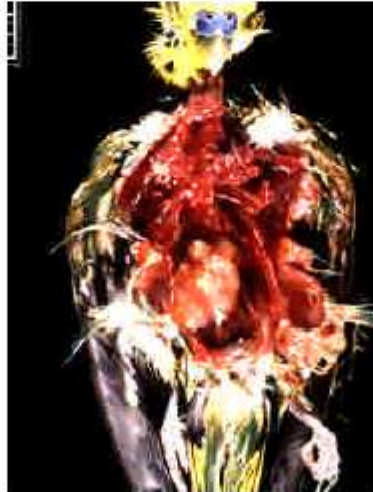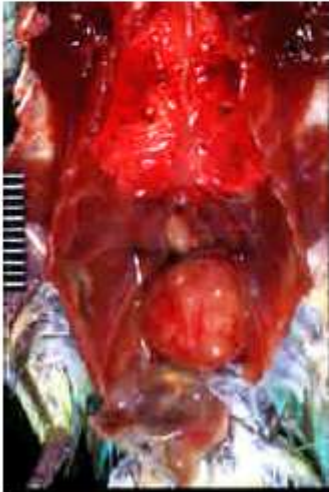- ☒ **Aetiology**: Papillomavirus suspected





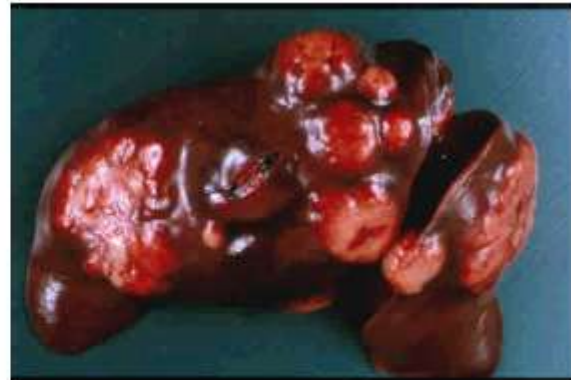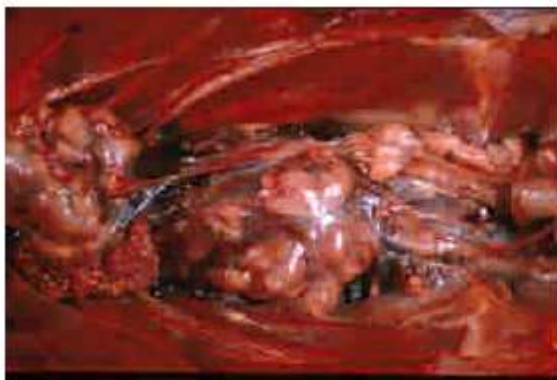## Tumours of unknown aetiology

- Kidney tumours
  - ☒ Carcinomas and adenomas
  - ☒ Budgerigars +++
  - ☒ Clinical signs: Unilateral or bilateral lameness and paralysis



## Tumours of unknown aetiology

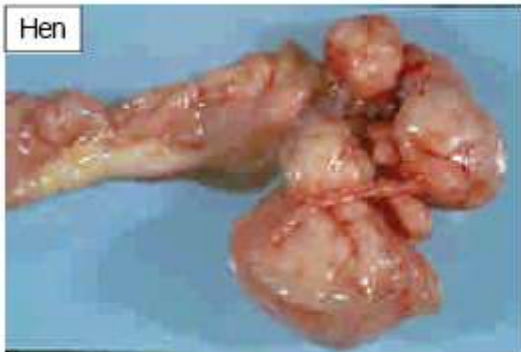- Kidney tumours:
  - ☒ Geese, Rhenan strain
  - ☒ Females breeders, 4th or 5th laying periods
  - ☒ Metastatic renal adenocarcinoma
  - ☒ Enzootic (30-40% at the slaughter House)
  - ☒ Aetiology ?



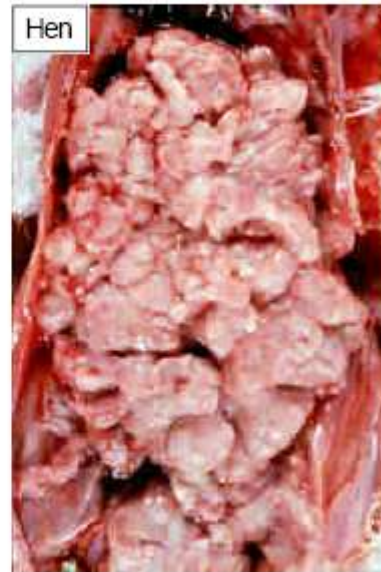## Tumours of unknown aetiology

- Ovarian tumours

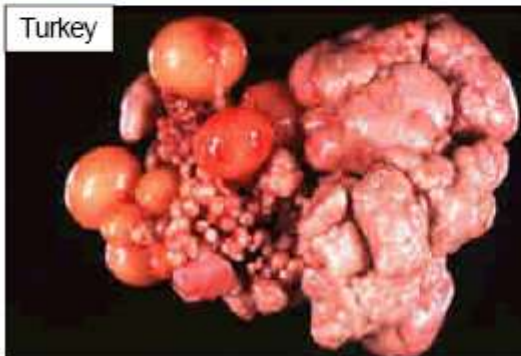- Adenocarcinoma in laying females



Hen



Hen

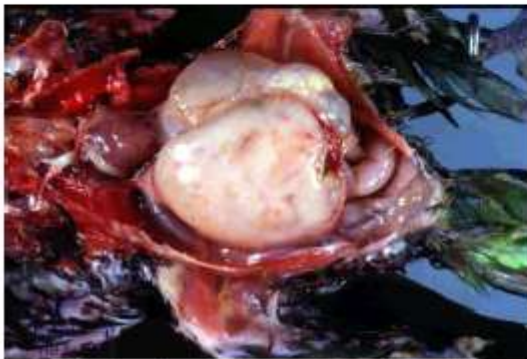


Turkey

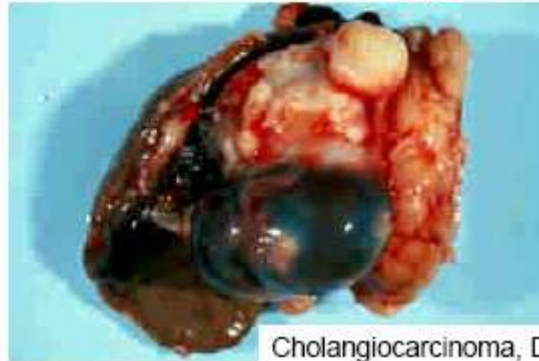Ovarian location in Marek's Disease

## Tumours of unknown aetiology

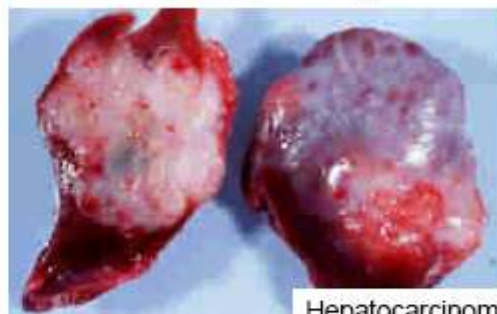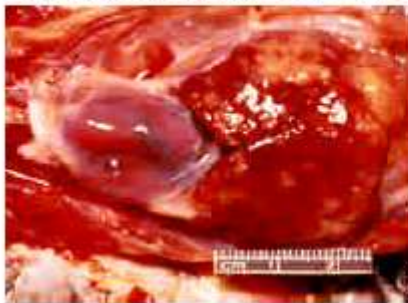
- Liver tumours



Cholangiocarcinoma, Grey Parrot



Cholangiocarcinoma, Duck



Hepatocarcinoma, Duck

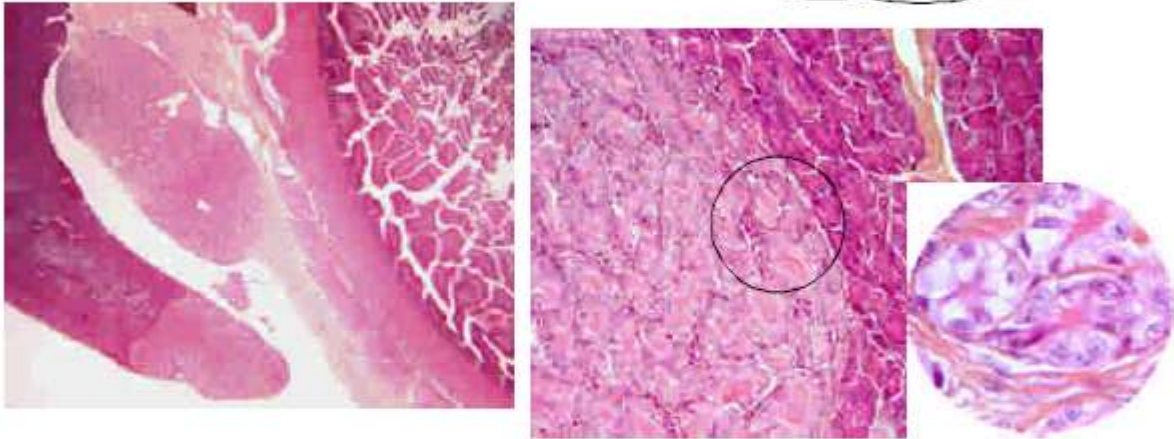
Hepatocarcinomas in ducks :  
Aflatoxicosis and association with Duck Hepatitis B virus



## Tumours of unknown aetiology

- Last histological case : T8, Guinea fowl

If you are still alive!



Multinodular epithelial tumour, involving the exocrine pancreas and extending to duodenal serosa.  
Tubular structures of large neoplastic cells with vesicular basal round nuclei and luminal acidophilic secretion:  
**Pancreatic acinar cell Adenocarcinoma**

**Differential diagnosis:** Metastatic abdominal adenocarcinoma derived from ovary or oviduct invading the serosa and pancreas parenchyma (no primary genital involvement in the present case).