

## Marie Curie Training Courses

Summer School 2007 – Avian V3/V4

### NON TUMORAL AVIAN VIRAL DISEASES WITH INCLUSION BODIES

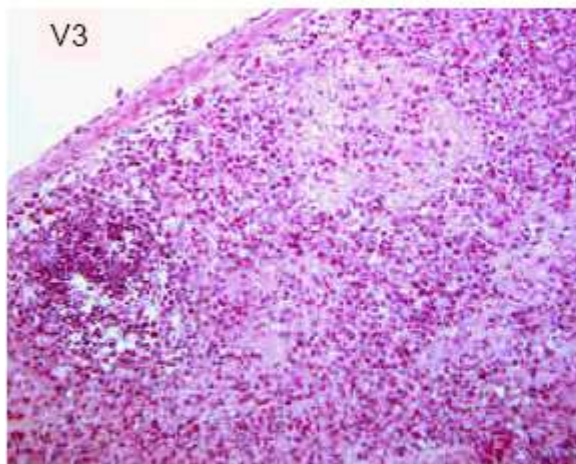
- Avian Adenovirus group II

- ▣ Histological lesions: Practical

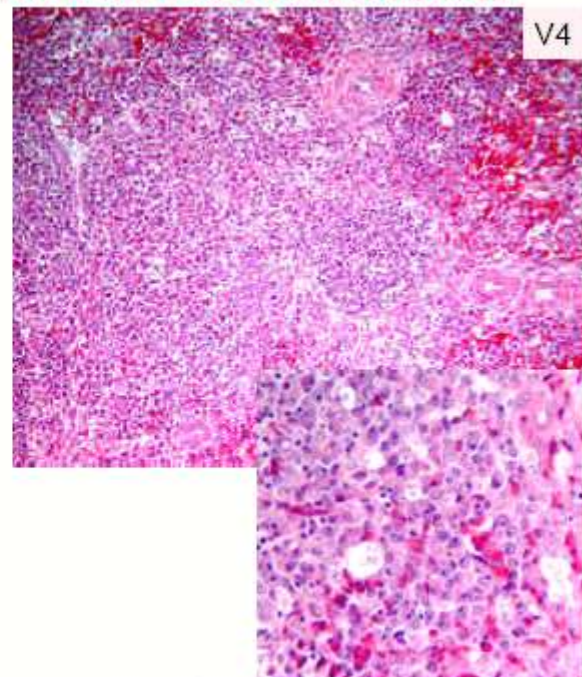
- ◆ V3: Spleen, young Pheasant, experimental inoculation
- ◆ V4: Spleen, Turkey, 5 weeks old, sudden onset of high mortality

### NON TUMORAL AVIAN VIRAL DISEASES WITH INCLUSION BODIES

- Avian Adenovirus group II : Histology



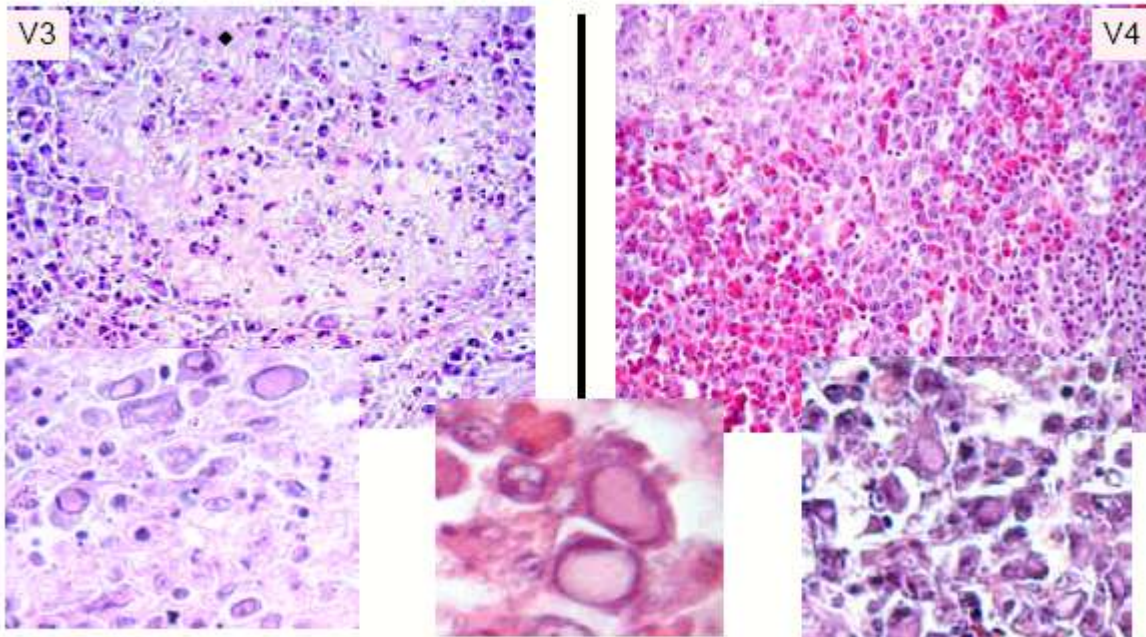
Acute, severe multifocal to coalescent fibrinoid necrosis of the red pulp with pycnosis of white pulp



Severe, multifocal, lymphomacrophagic hyperplasia of white and red pulp, lymphoid cells pycnosis and « starry sky »

## NON TUMORAL AVIAN VIRAL DISEASES WITH INCLUSION BODIES

- Avian Adenovirus group II : Histology

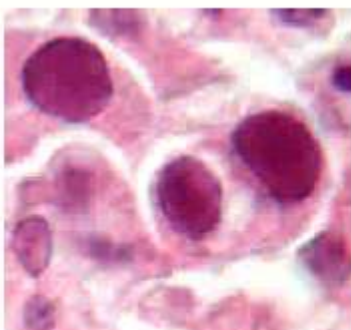


Pale, slightly basophilic, bad defined inclusion bodies with chromatin margination and nucleus hypertrophy in lymphoblastic cells and macrophages

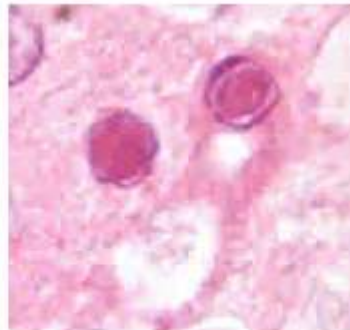
## NON TUMORAL AVIAN VIRAL DISEASES WITH INCLUSION BODIES

- Avian Adenovirus: Conclusion

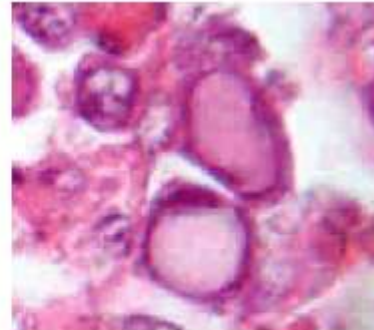
- ✦ Frequent infectious viral diseases in avian
- ✦ Many different avian species (poultry, wild, cage and game birds)
- ✦ Located in numerous different tissues (liver, spleen, macrophages, respiratory and glandular epitheliums)
- ✦ Lesions
  - ◆ Severe, acute, multifocal or extensive necrosis +++
  - ◆ **Inclusions bodies: constant and often numerous**



Adenoviruses group I  
(acute, severe form)



Adenoviruses group I  
(subacute, mild form)



Adenoviruses group II