ECVP/ESVP Summer School in Veterinary Pathology

Marie Curie Training Courses

Summer School 2004 – Non-Human Primates Case 36
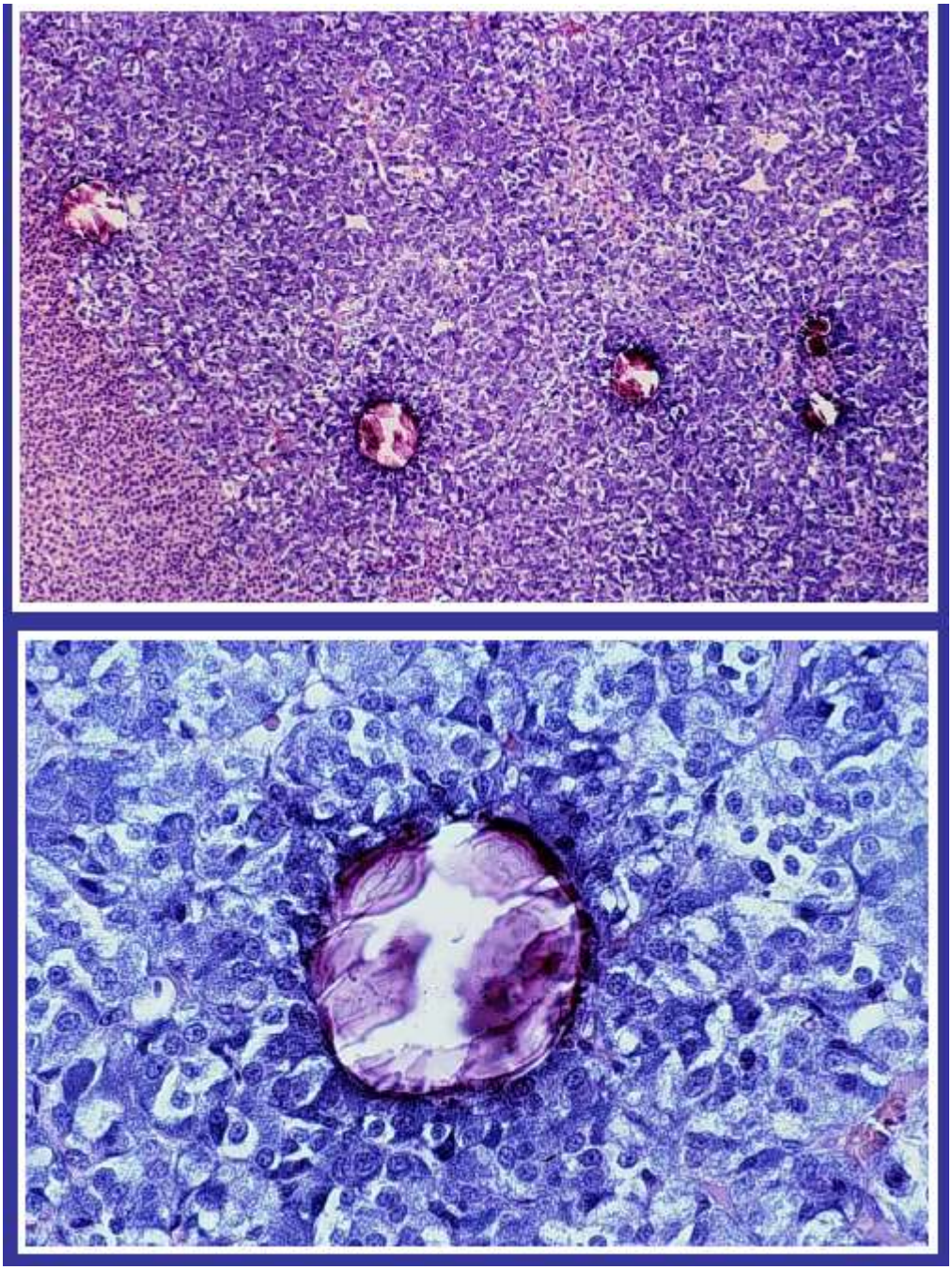
Case No. 36	**Organ: adrenal gland**	
Species: Rhesus monkey (*M. mulatta*)		**female, adult**
Case history: Experimental repeated SIV infection; 5 years after first infection; no clinical signs		
Gross pathology: no abnormality detected		
Microscopical description:		
Pathohistological diagnosis: **Calcification, focal**		
Aetiology/Comment: **idiopathic**