

Marie Curie Training Courses

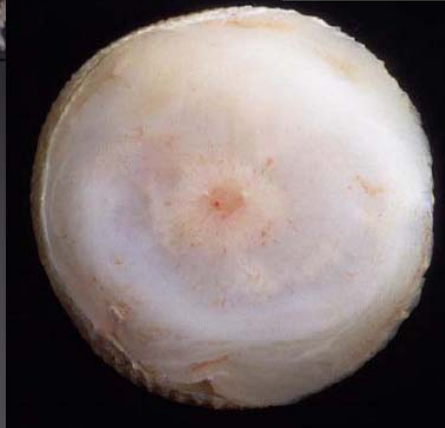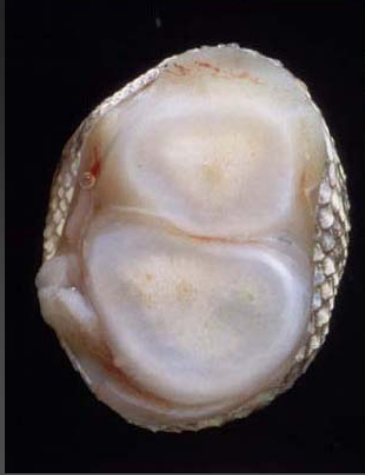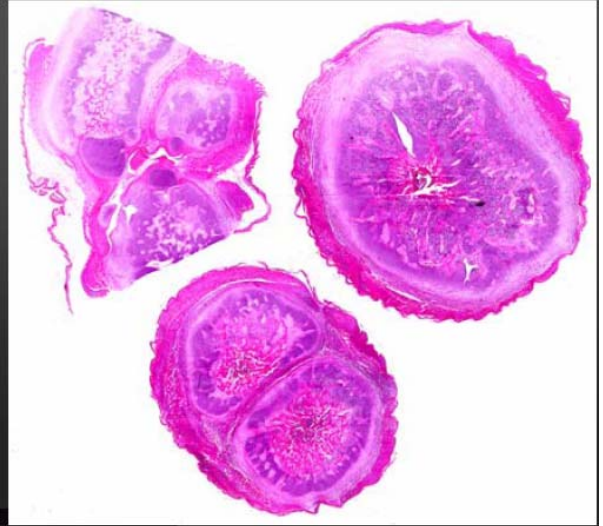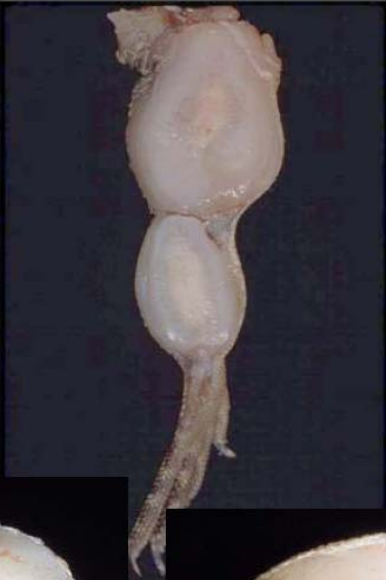Summer School 2004 – Reptile Case 14

14 Lizard

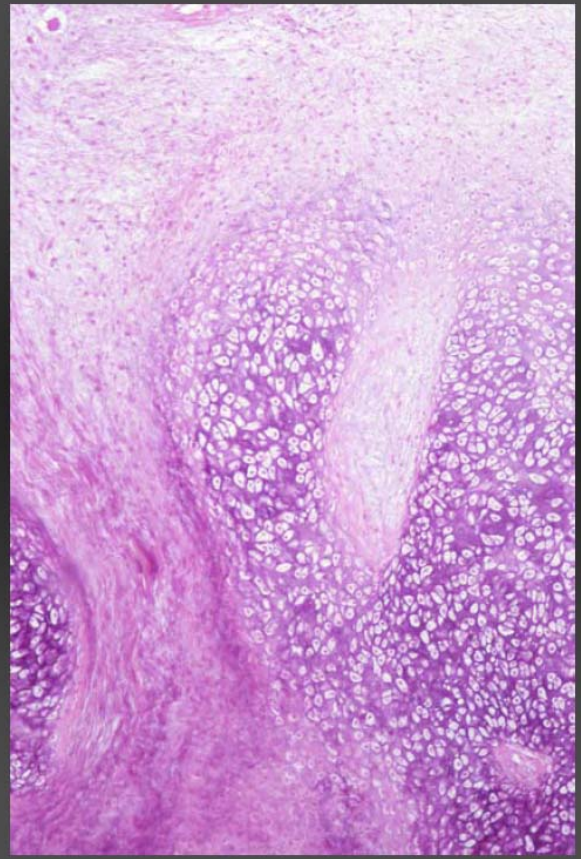
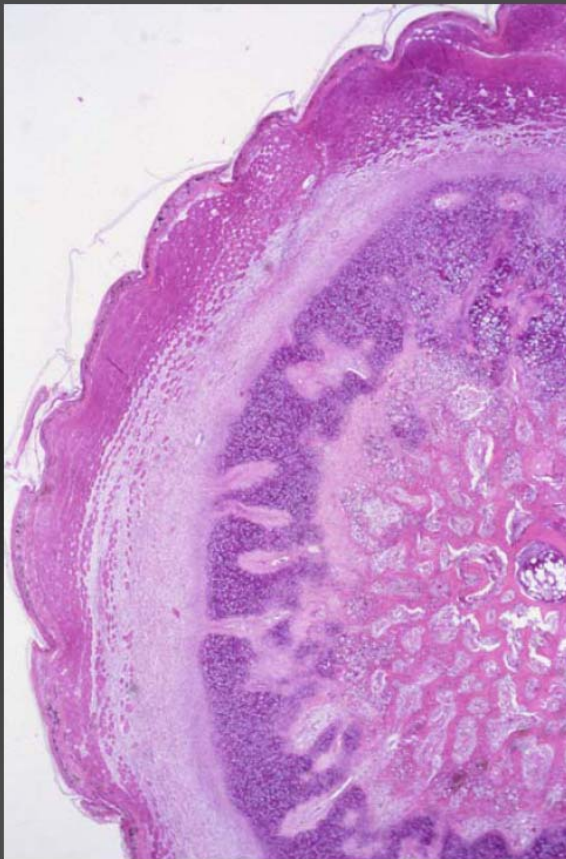
Ctenosaura sp.

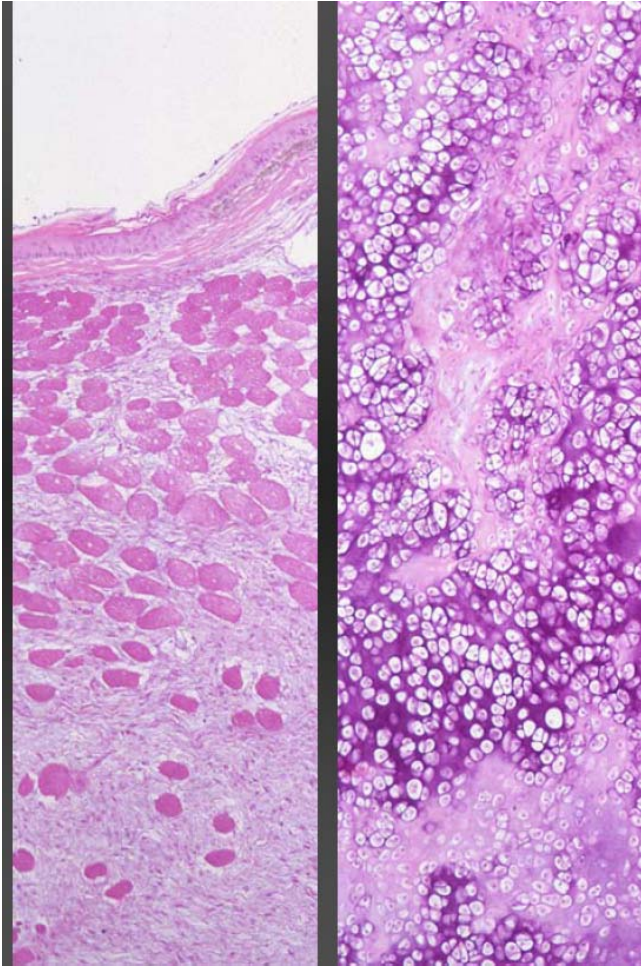


14 Lizard
Ctenosaura sp.



14 Lizard





14 Lizard, juvenile, male

Morphologic diagnosis:

bone: periosteal osteocartilaginous
proliferation and
myxoid fibrosis / endosteal / periosteal
severe, circular

Aetiologic diagnosis:

metabolic bone disease (MBD)