

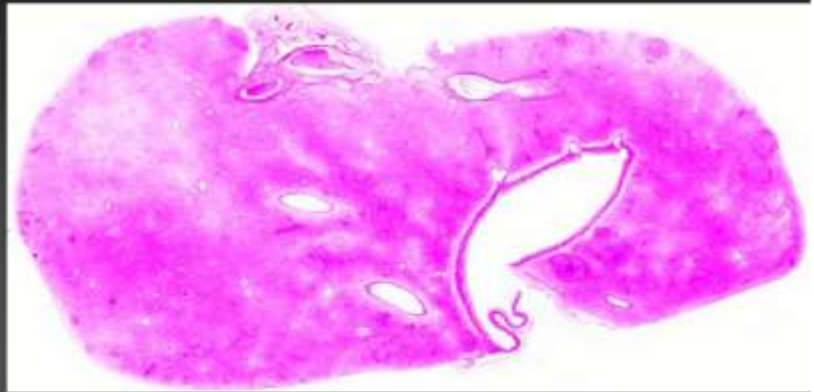
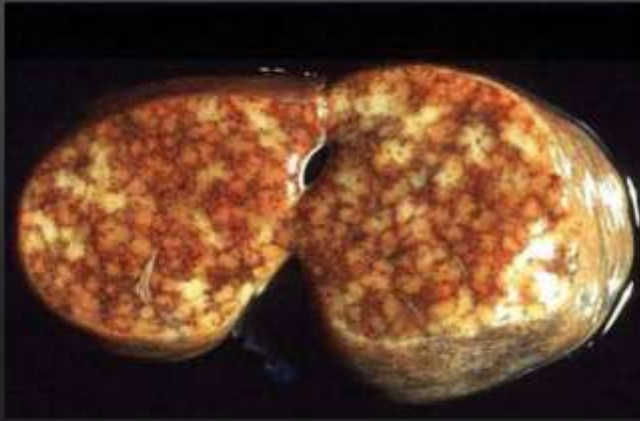## Marie Curie Training Courses

Summer School 2004 – Reptile Case 15

# 15 Snake  
*Boa constrictor*  
Liver



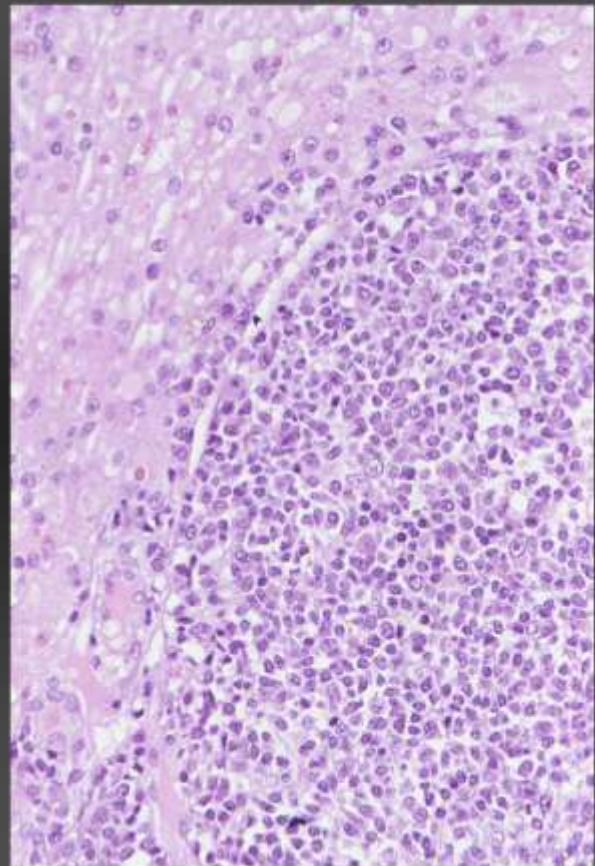
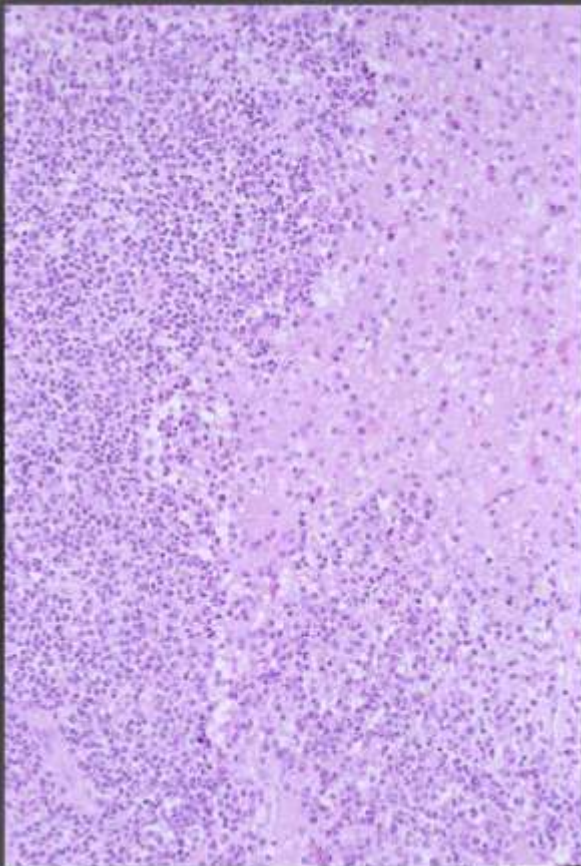
**# 15 Snake**  
*Boa constrictor*  
Liver

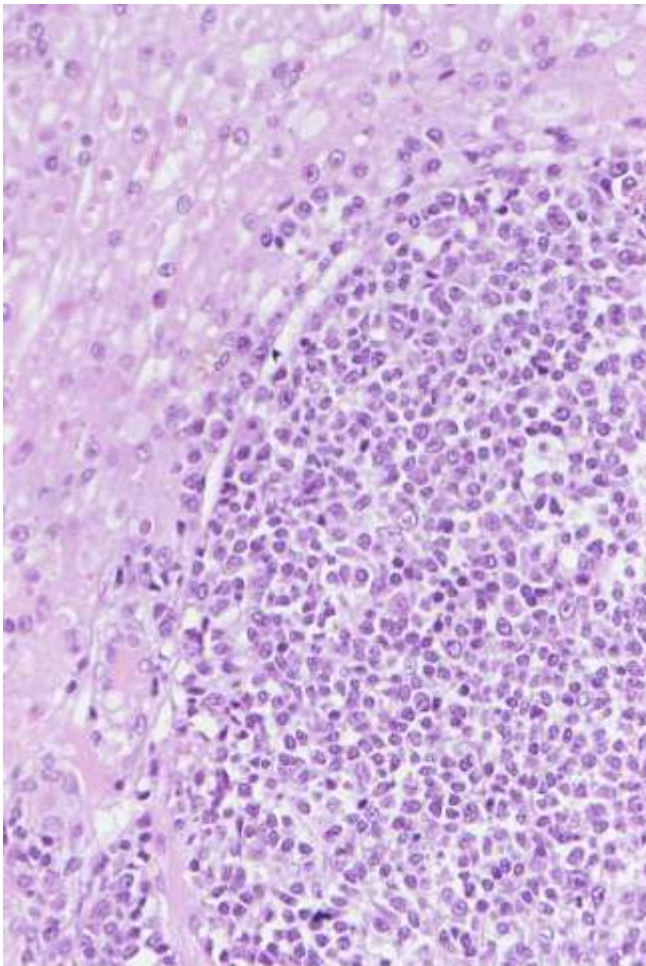


**# 15 Snake**

*Boa constrictor*

Liver





**# 15 Snake**  
*Boa constrictor*

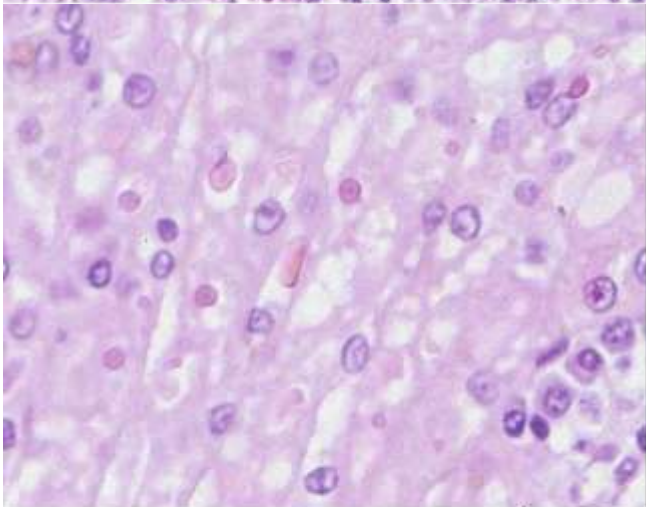
*Morphologic diagnosis:*

Liver:

1. lymphosarcoma
2. multifocal intracytoplasmic eosinophilic inclusion bodies in hepatocytes and lymphocytes

Aetiologic Diagnosis: IBD

? retroviral infection



**# 15 Snake**  
*Boa constrictor*

*Morphologic diagnosis:*

Liver:

1. lymphosarcoma
2. multifocal intracytoplasmic eosinophilic inclusion bodies in hepatocytes and lymphocytes

