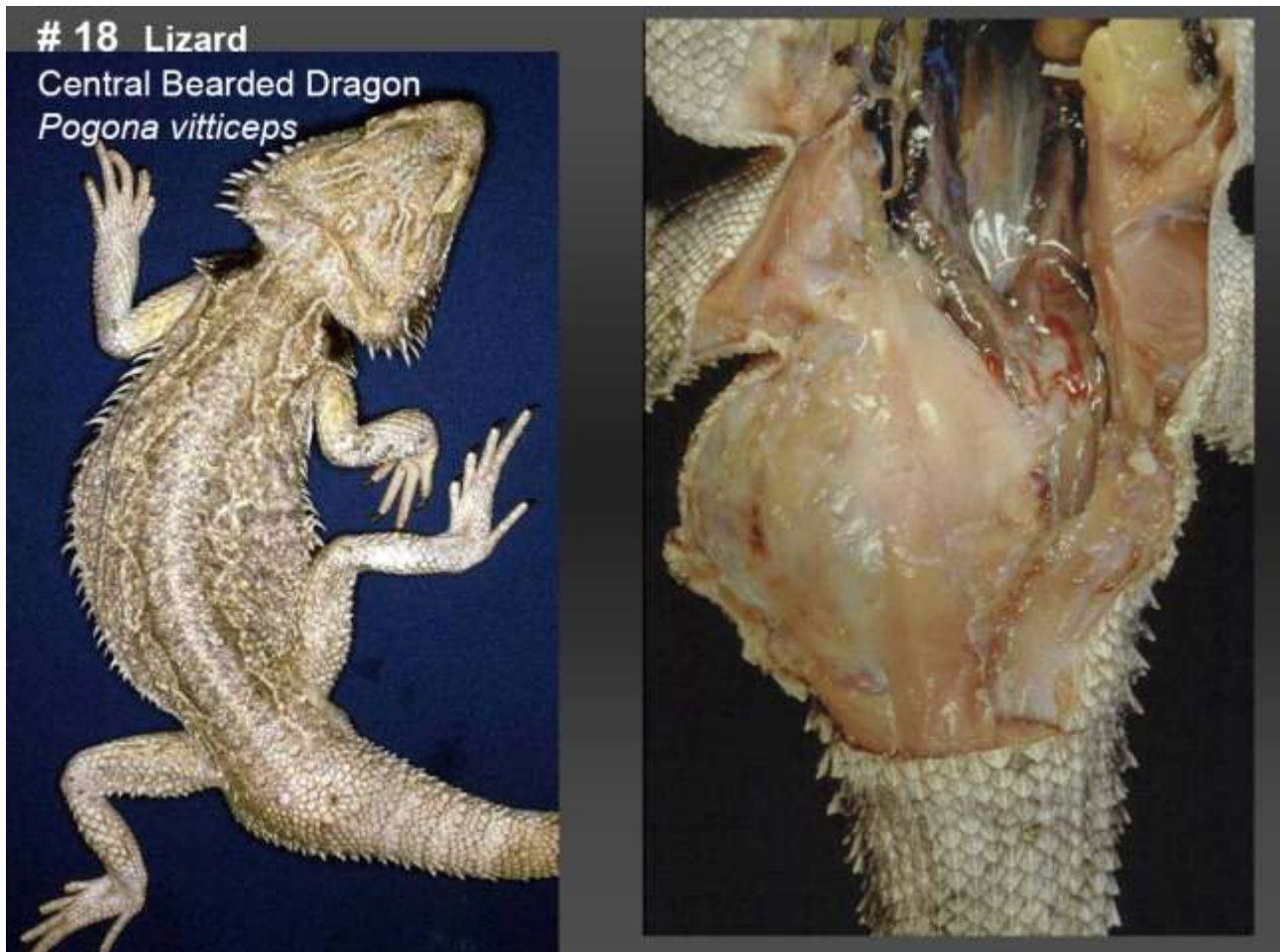

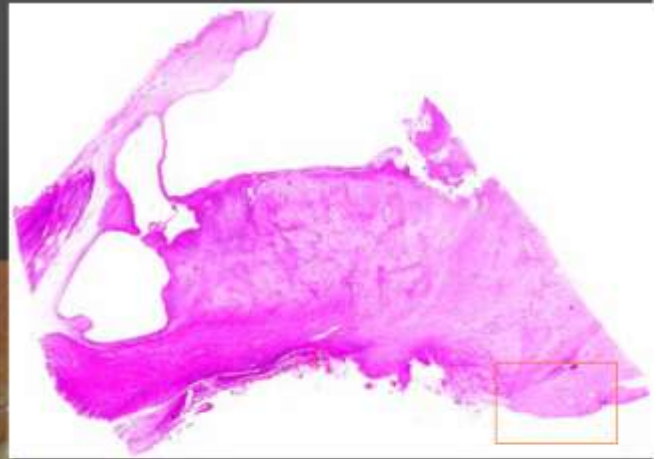
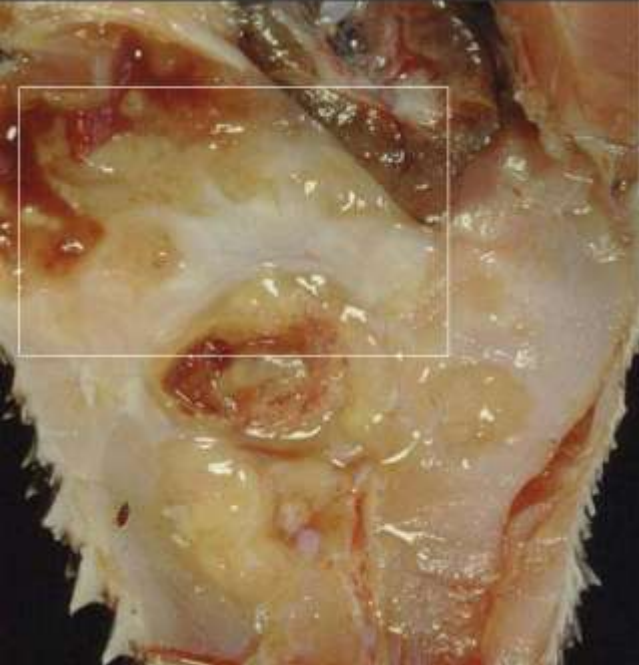
Marie Curie Training Courses

Summer School 2004 – Reptile Case 18



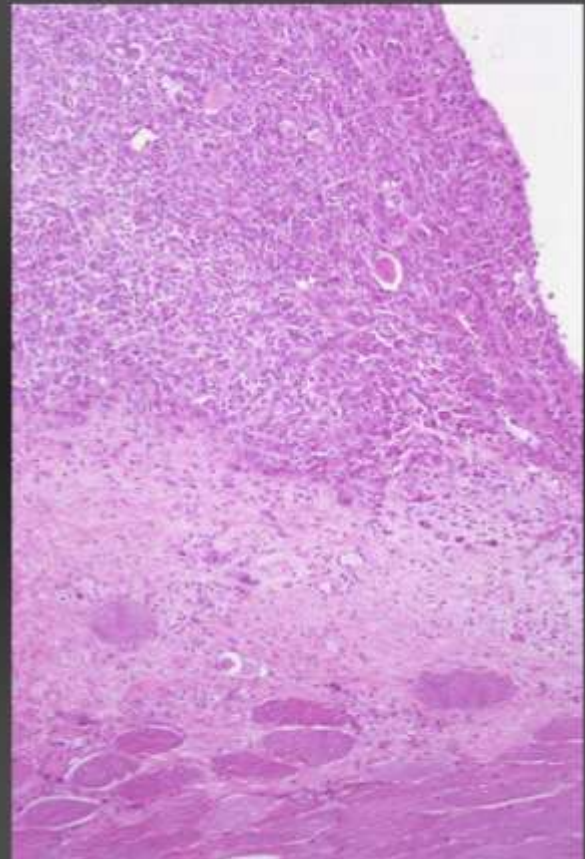
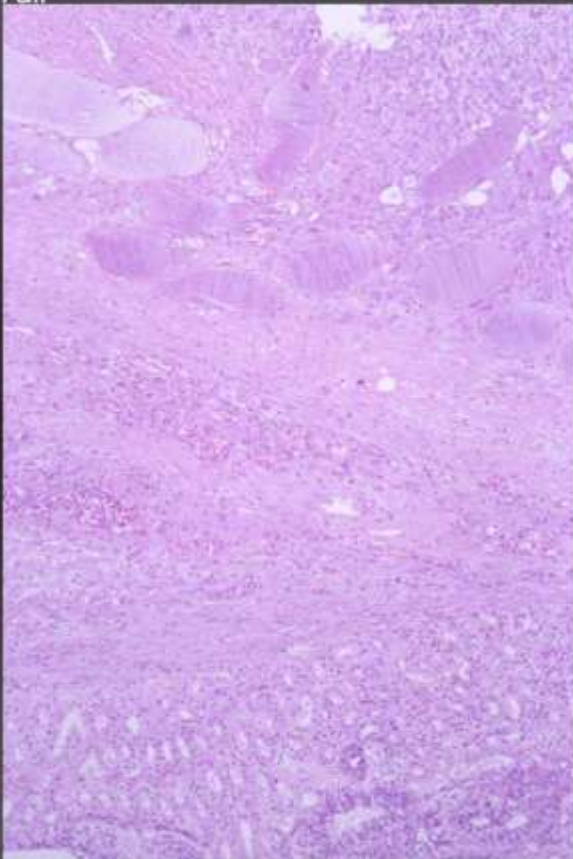
18 Lizard
Central Bearded Dragon
Pogona vitticeps

Tail



18 Lizard Central Bearded Dragon
Tail

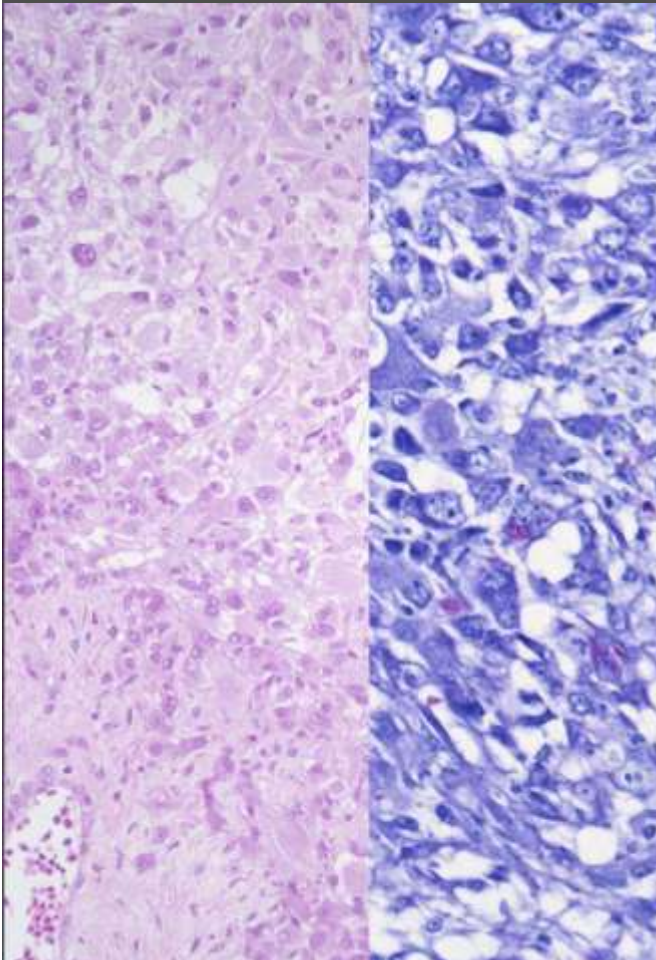
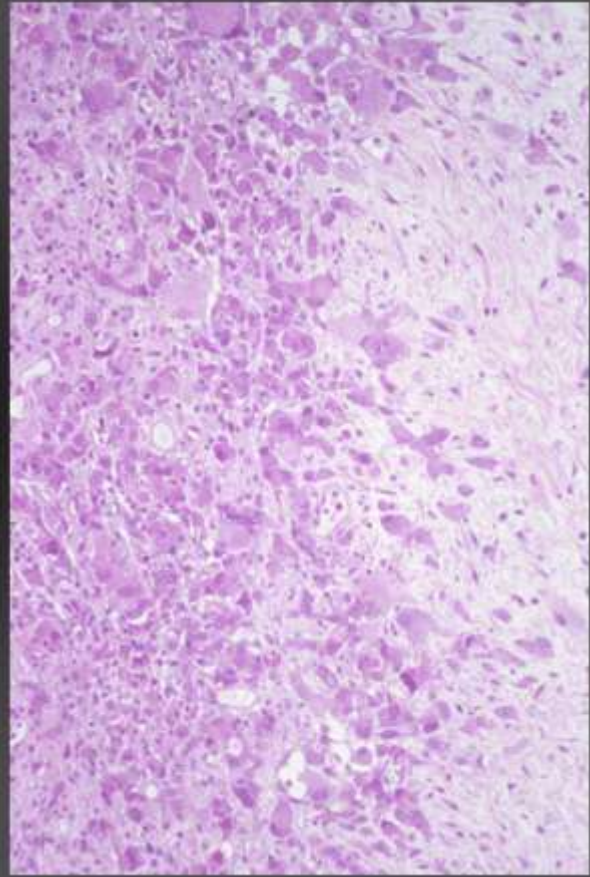
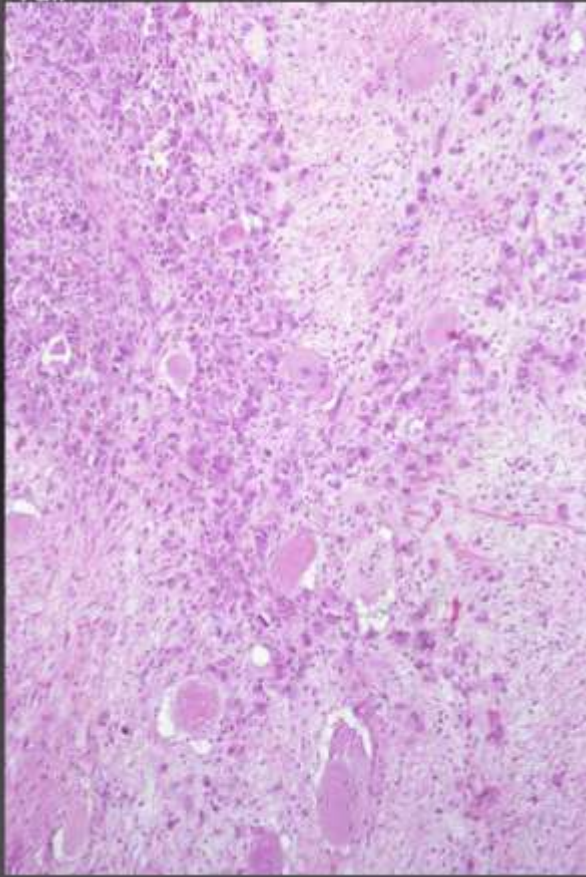
Pogona vitticeps



18 Lizard
Tail

Central Bearded Dragon

Pogona vitticeps



18 Lizard
Central Bearded Dragon
Pogona vitticeps

Morphologic Diagnoses:

Tail/pericloacal region:

pyogranulomatous, focally necrotising myositis,
perimyositis/panniculitis

(and ? adenitis of pericloacal glands)

Aetiologic diagnosis: Mycobacteriosis

ZN: positive rodshaped intracellular bacteria
(*Mycobacterium sp.*)