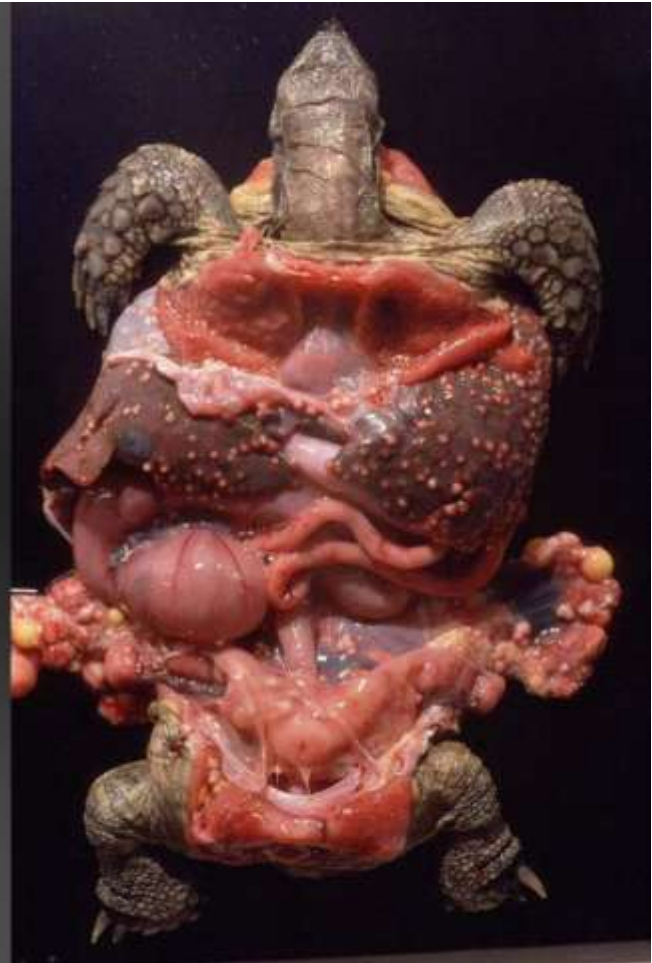

Marie Curie Training Courses

Summer School 2004 – Reptile Case 20

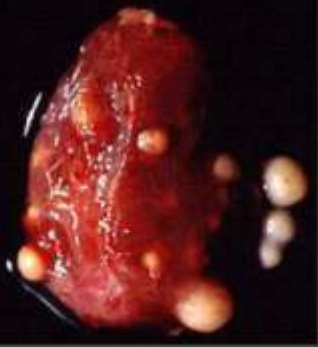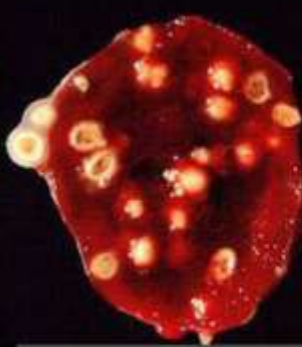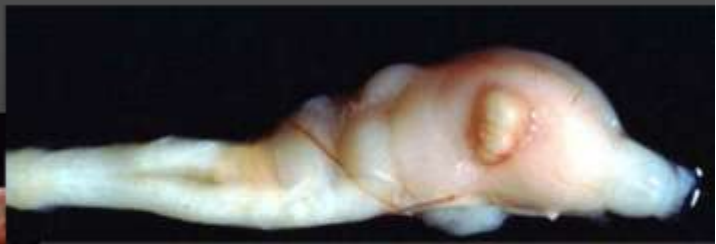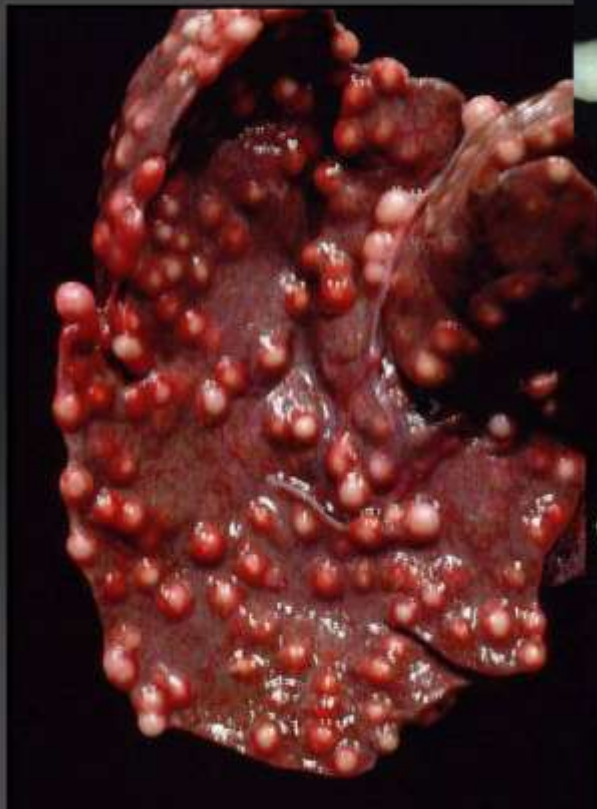20 Tortoise

Testudo marginata



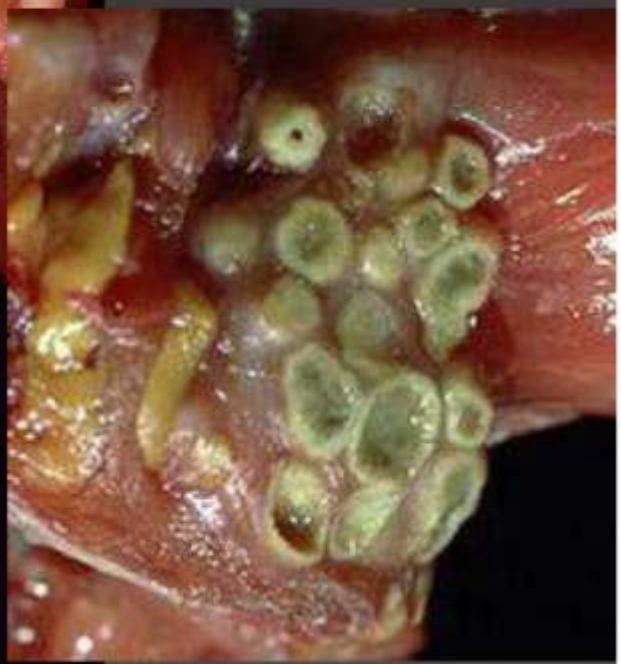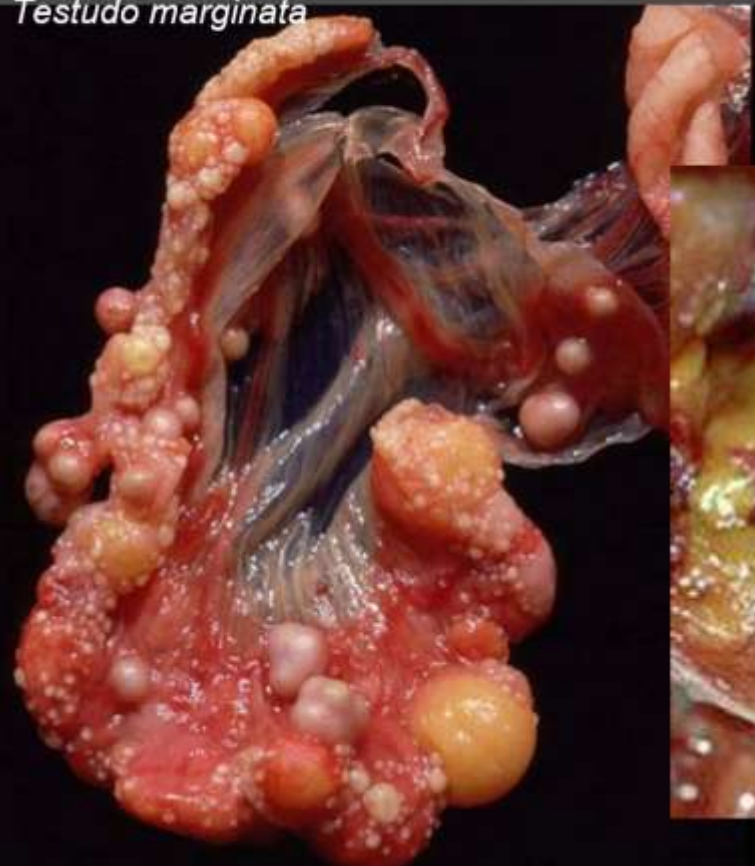
20 Tortoise

Testudo marginata



20 Tortoise

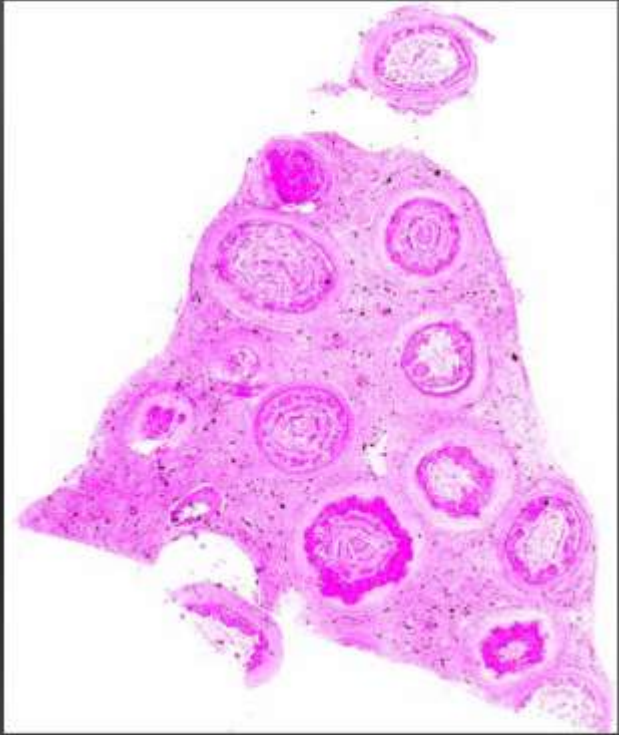
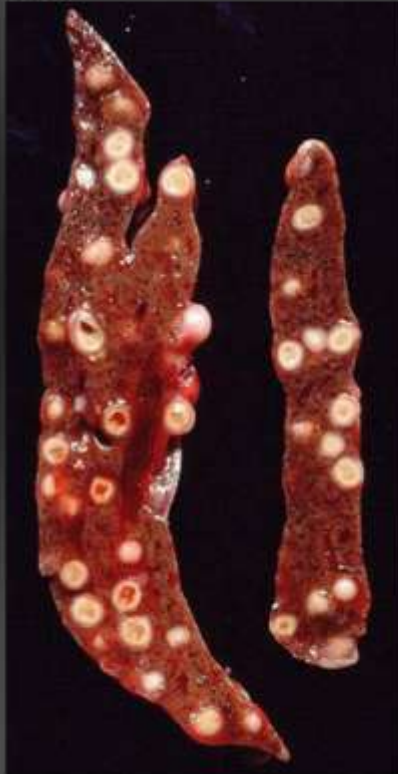Testudo marginata



20 Tortoise

Testudo marginata

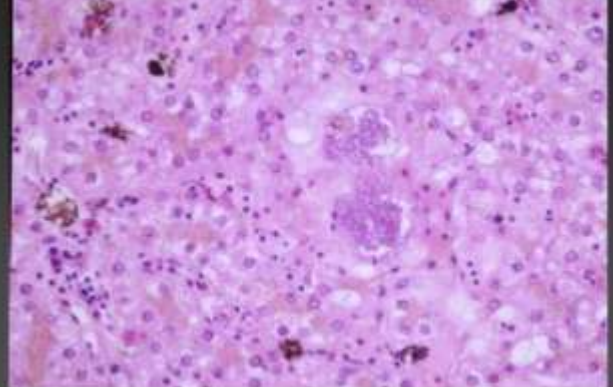
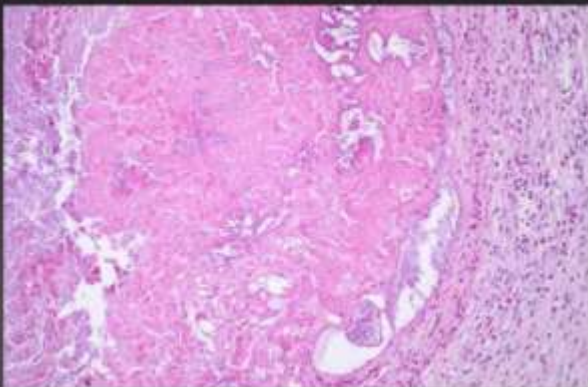
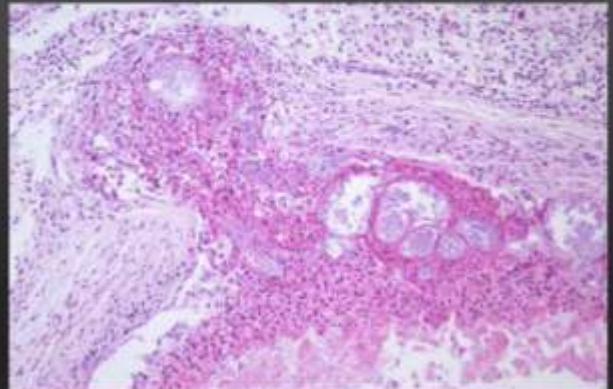
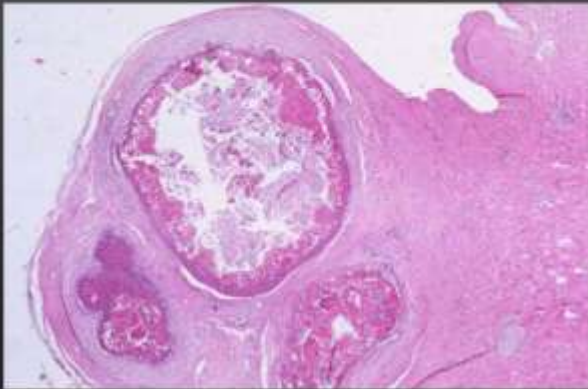
Liver

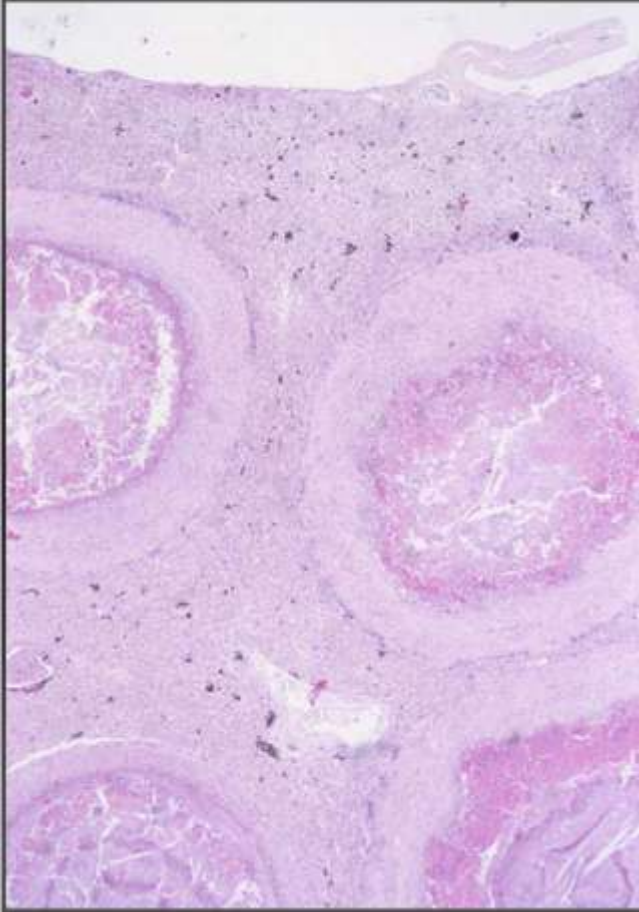


20 Tortoise

Testudo marginata

Serratia marcescens infection





20 Tortoise
Testudo marginata

Morphologic diagnosis:

Liver:

pyogranulomatous hepatitis with abscess formation, multifocal, severe, subacute to chronic

Aetiologic diagnosis:

Serratia marcescens infection

temperature range: 4-30°C