

Marie Curie Training Courses

Summer School 2005 – Marine Mammals Case 2

Case history

Case 2

- Striped dolphin (*Stenella coeruleoalba*), adult female, 215-cm long, 80 kg, stranded at the Catalonian coast in March 1997

Gross findings

- Generalised icterus (subcutaneous tissue, aorta, pulmonary vessels, renal pelvis, cerebrospinal fluid), and subcutaneous haemorrhages
- Hepatic congestion
- Hypertrophy of mesenteric lymph node
- Bulla, 4 cm in diameter, left lung
- Usual parasitism in skin, lung, and gastric mucosa

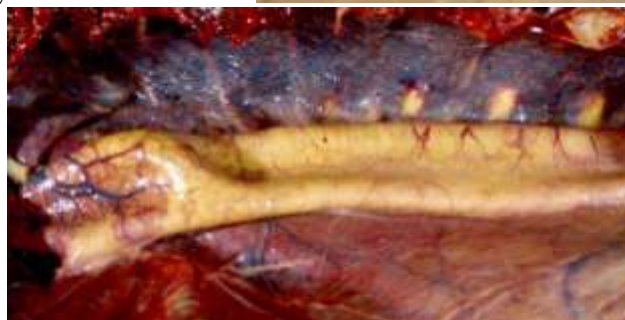Case 2

Icterus

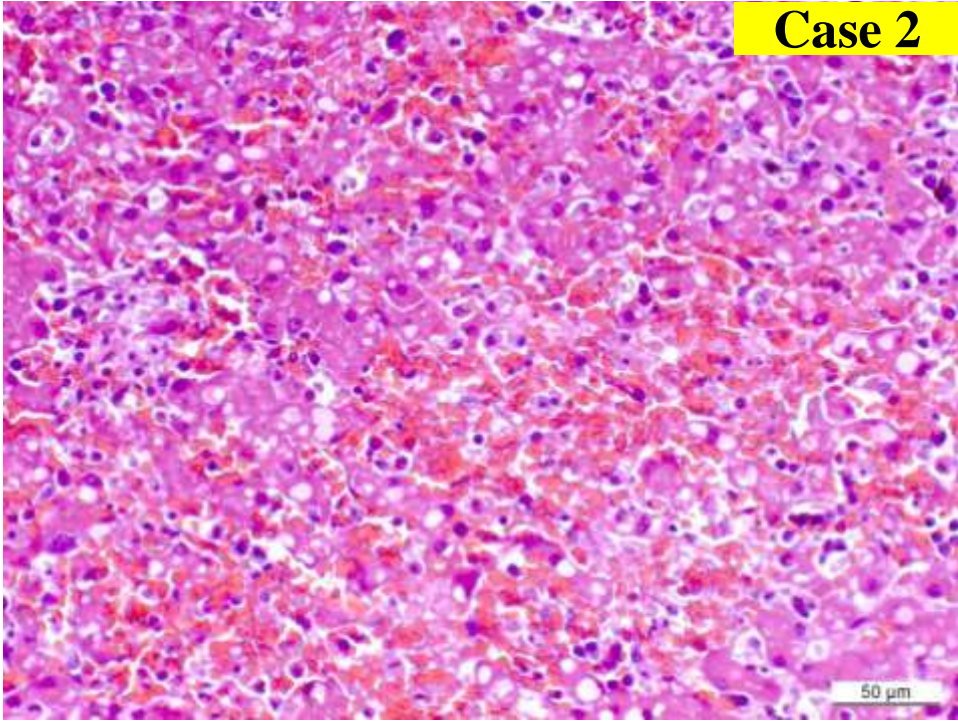
Cerebrospinal and ocular chamber fluids with yellowish color (icterus)



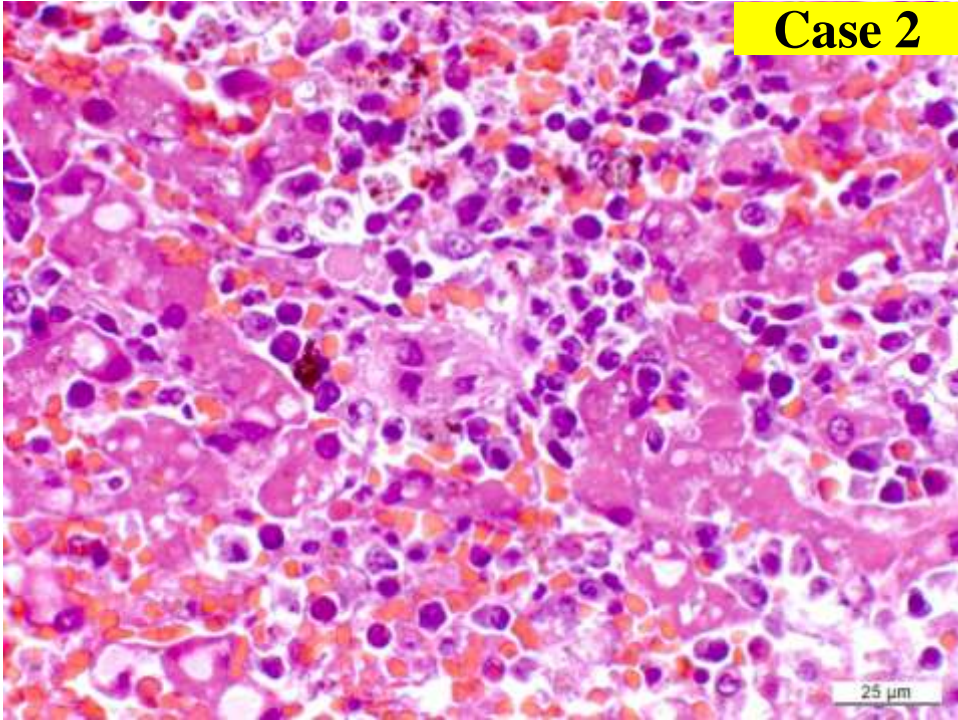
A. aorta with a yellowish color



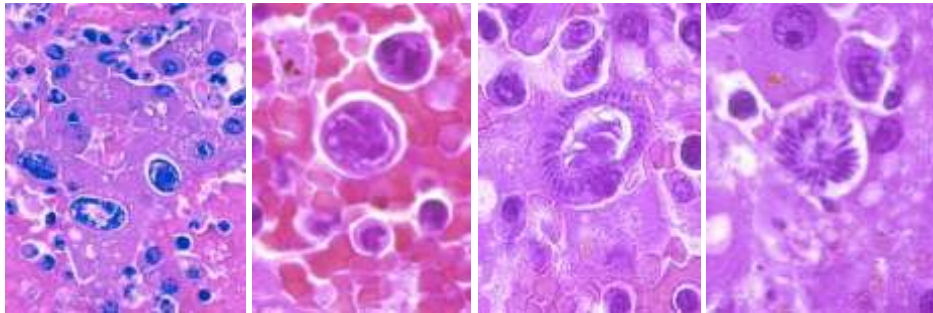
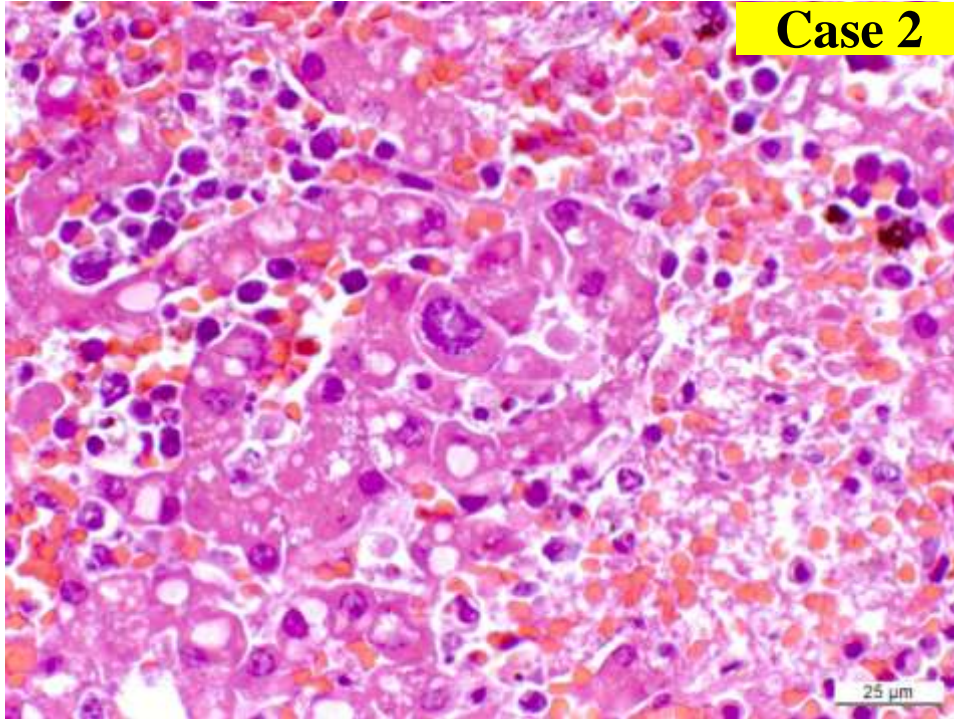
Case 2



Case 2



Case 2



Histopathologic findings

- Acute multifocal necrotising hepatitis
- Intrahepatocytic *Sarcocystis*-like apicomplexan protozoal forms in several development stages
- IHC negative for *S.neurona*
- EM: morphologic similarities with *S.canis*

First description in a cetacean of a *sarcocystis*-associated hepatitis, hepatic failure and icterus (cause of death)

Resendes et al. (2002). Hepatic Sarcosystosis in a Striped Dolphin (*Stenella coeruleoalba*) from the Spanish mediterranean coast. J. Parasitol. 88(1) 226-209

Hepatic sarcocystosis is a new disease in cetaceans

Descriptions of hepatic sarcocystosis in mammals

- Sea lion (*Zalophus californianus*) (Mense, 1992)
- Polar bear (*Ursus maritimus*) (Garner, 1997)
- Black bear (*Ursus americanus*) (Zeaman, 1993)
- Chinchilla (Rakich, 1992)

Sarcocystis-like infection in cetaceans

Muscular sarcocysts without inflammatory reaction

- Striped dolphin (*Stenella coeruleoalba*) (Dailey, 1978)
- Pilot whale (*Globicephala melaena*) (Cowen, 1966)
- Sperm whale (*Physeter catadon*) (Cowen, 1967)