

Marie Curie Training Courses

Summer School 2007 – Avian V1/V2

NON TUMORAL AVIAN VIRAL DISEASES WITH INCLUSION BODIES

- Avian Adenovirus group I

- ☒ Inclusion Body Hepatitis: Chicken

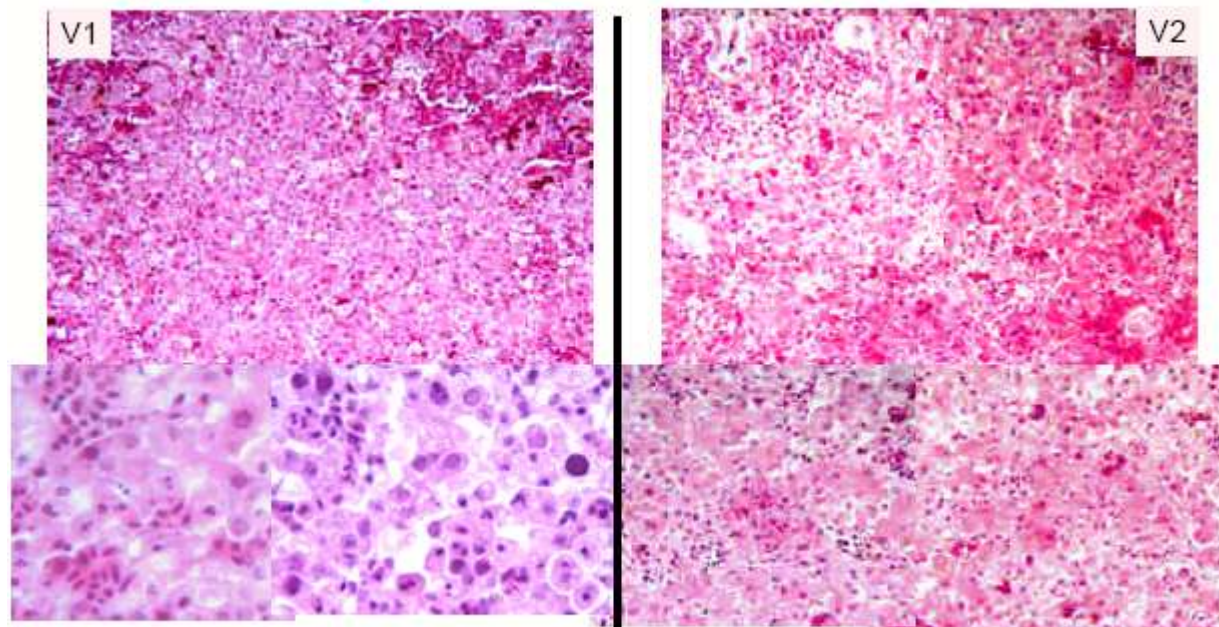
- ☒ Histological lesions: Practical

- ◆ V1 : Liver, chicken, 3 weeks old, sudden onset of mortality

- ◆ V2 : Liver, chicken, 4 weeks old, sudden onset of mortality

NON TUMORAL AVIAN VIRAL DISEASES WITH INCLUSION BODIES

- Avian Adenovirus group I : Inclusion Body Hepatitis: Histology

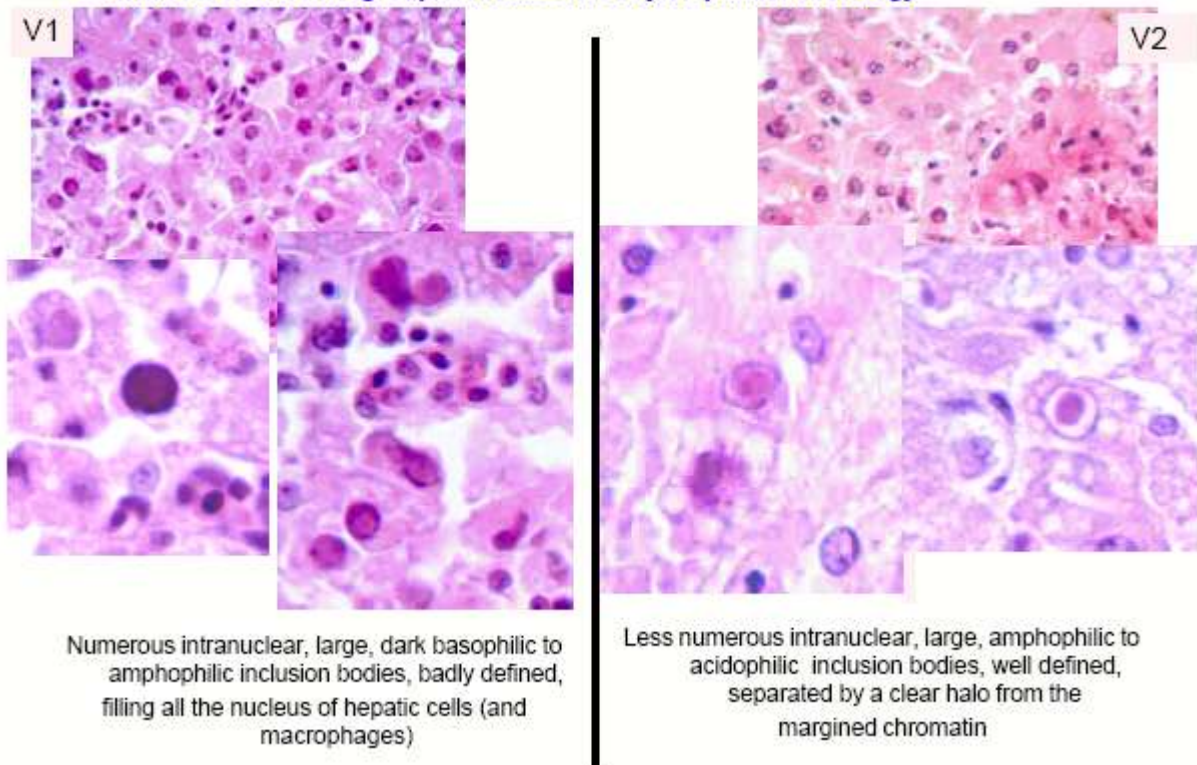


Severe, extensive (generalized), necrotizing Hepatitis :
Acute, extensive coagulative necrosis
+ hyperemia and multifocal hemorrhages

Multifocal marked necrotizing Hepatitis
+ hyperemia and interstitial inflammatory infiltrate

NON TUMORAL AVIAN VIRAL DISEASES WITH INCLUSION BODIES

- Avian Adenovirus group I: Inclusion Body Hepatitis: Histology



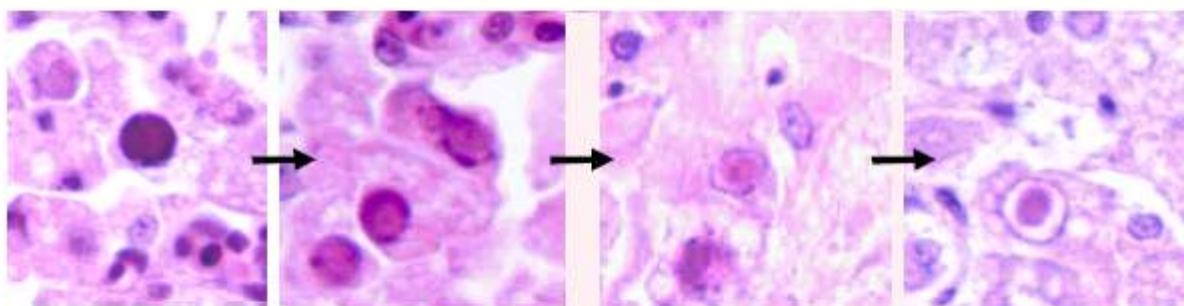
NON TUMORAL AVIAN VIRAL DISEASES WITH INCLUSION BODIES

- Avian Adenovirus group I

Inclusion Body Hepatitis

↩ Histological lesions: CONCLUSION

Acute, severe, multifocal or extensive necrotizing Hepatitis associated with numerous basophilic to acidophilic intranuclear inclusion bodies in hepatic cells (and macrophages)



Evolution of the morphology of inclusion bodies

NON TUMORAL AVIAN VIRAL DISEASES WITH INCLUSION BODIES

- Other Avian Adenovirus group I : A quick overview

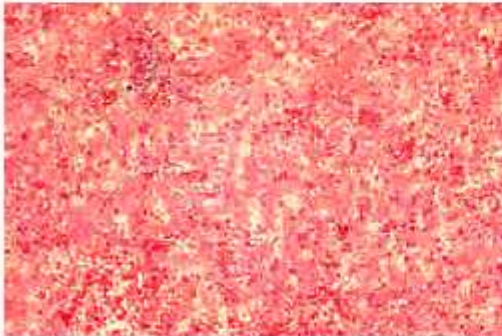
- ☒ **Pigeon adenovirus**

- ☛ Classical form: sporadic form

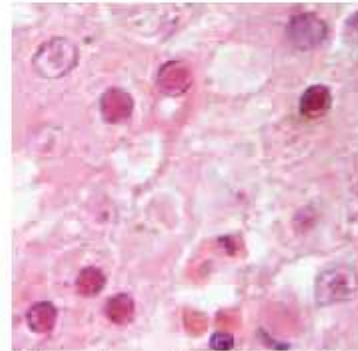
- ◆ Pigeons less than 1 year. Catarrhal enteritis with diarrhea
 - ◆ High morbidity (\pm 100%), low mortality (secondary E Coli infection)

- ☛ Severe form: **Necrotizing Hepatitis**

- ◆ Pigeons of all age. Low morbidity, high mortality (30 to 100% of affected birds)
 - ◆ Bacterial complications frequent



Moderate multifocal necrotizing hepatitis with focal interstitial inflammatory cells infiltration, hyperemia and hemorrhages

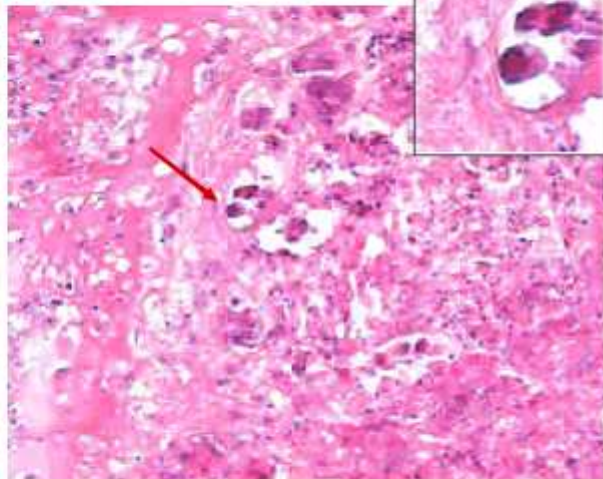
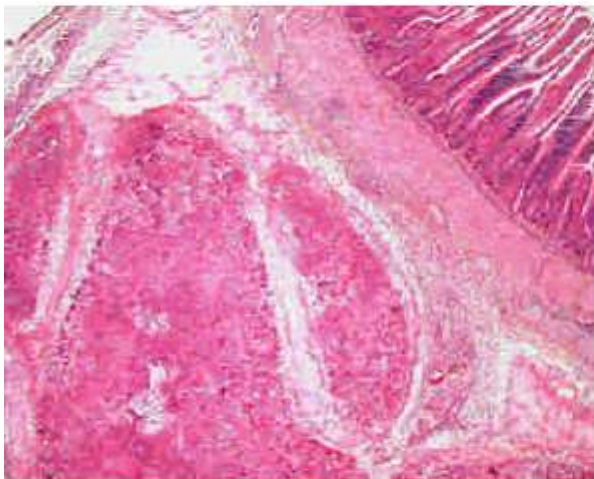


Numerous intranuclear acidophilic inclusion bodies, well defined, surrounded by a clear halo

NON TUMORAL AVIAN VIRAL DISEASES WITH INCLUSION BODIES

- Other Avian Adenovirus group I : a quick overview

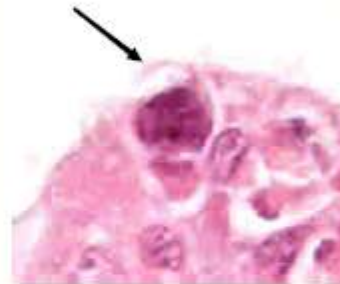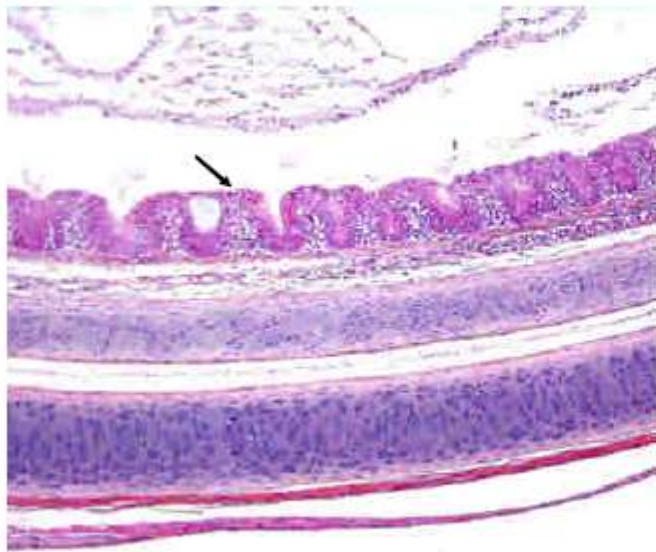
- ☒ **Necrotizing Pancreatitis of Guinea Fowl**



Acute, severe, diffuse, subtotal necrosis of pancreas parenchyma with perilobular inflammatory edema. Few intranuclear, basophilic, badly defined, inclusion bodies

NON TUMORAL AVIAN VIRAL DISEASES WITH INCLUSION BODIES

- Other Avian Adenovirus group I: a quick overview
 - ☒ Respiratory syndromes (Quail bronchitis, turkey, cage birds)



Subacute, moderate to severe exudative tracheitis and bronchitis.
Few intranuclear, basophilic, badly defined, inclusion bodies

NON TUMORAL AVIAN VIRAL DISEASES WITH INCLUSION BODIES

- Avian Adenovirus group II

- ☒ Turkey Hemorrhagic Enteritis and Marble Spleen Disease

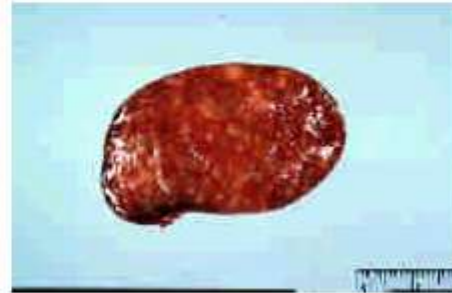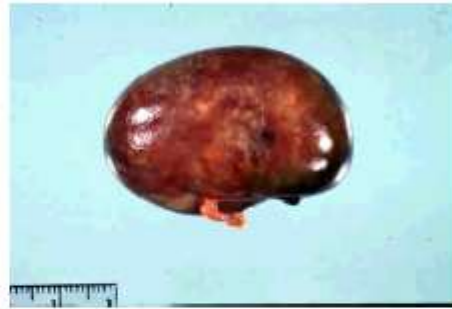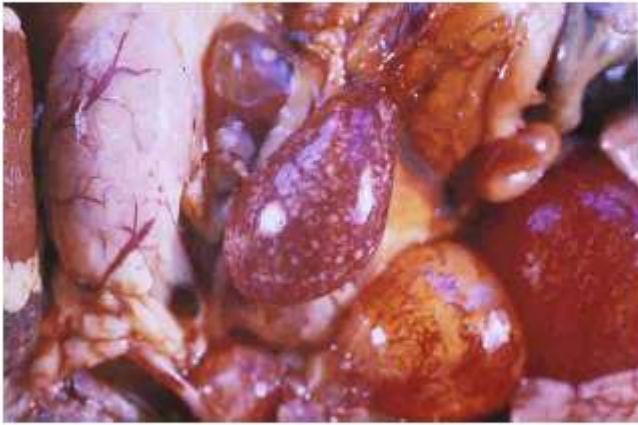
- ☒ Adenoviruses group II (Siadenovirus), the 2 causing viruses are serologically indistinguishable
- ☒ Turkey Hemorrhagic Enteritis
 - ◆ 4 weeks of age and older
 - ◆ Acute fatal disease with depression and bloody dropping
 - ◆ Variation in virulence from 1 to 60% of mortality
 - ◆ Immunosuppression in surviving birds
- ☒ Marble Spleen Disease
 - ◆ Confinement reared Pheasants
 - ◆ Between 3 to 8 months of age
 - ◆ Depression and mortality
 - ◆ Mortality : 5 to 20%

NON TUMORAL AVIAN VIRAL DISEASES WITH INCLUSION BODIES

- Avian Adenovirus Group II

- ☑ **Marble Spleen Disease (pheasant)**

- ↳ Gross lesions



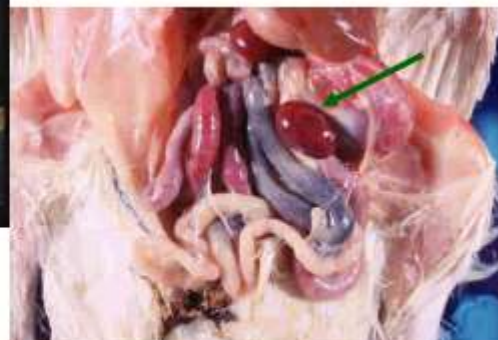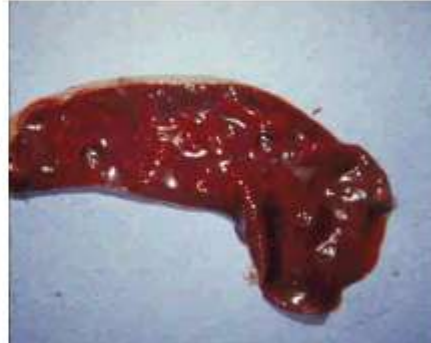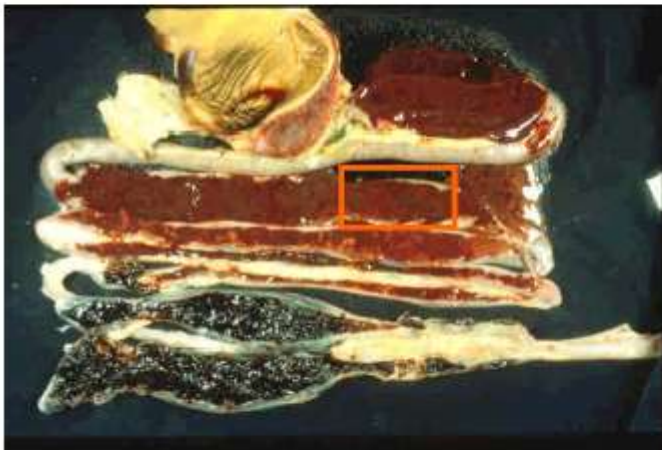
Acute, severe, multifocal to coalescing necrotizing splenitis with important splenomegaly : "marble spleen"

NON TUMORAL AVIAN VIRAL DISEASES WITH INCLUSION BODIES

- Avian Adenovirus group II

- ☑ **Turkey Hemorrhagic Enteritis**

- ↳ Gross lesions



Acute, diffuse, extremely severe necrotizing and hemorrhagic enteritis and typhlitis

Important, diffuse splenomegaly → HISTOLOGY