

## Marie Curie Training Courses

Summer School 2007 – Avian V7/V8

### NON TUMORAL AVIAN VIRAL DISEASES WITH INCLUSION BODIES

- Avian Poxvirus

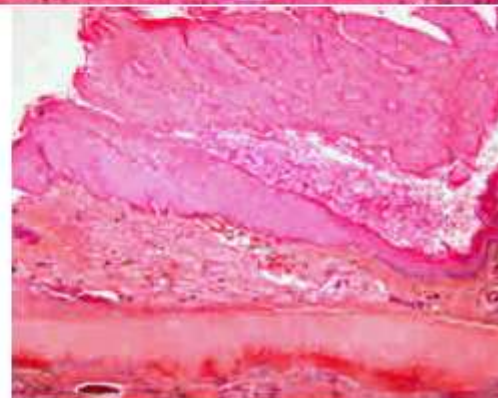
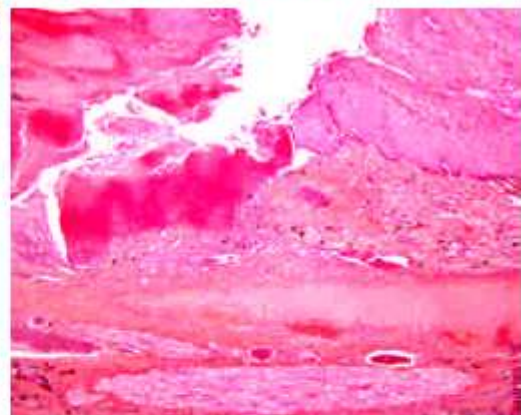
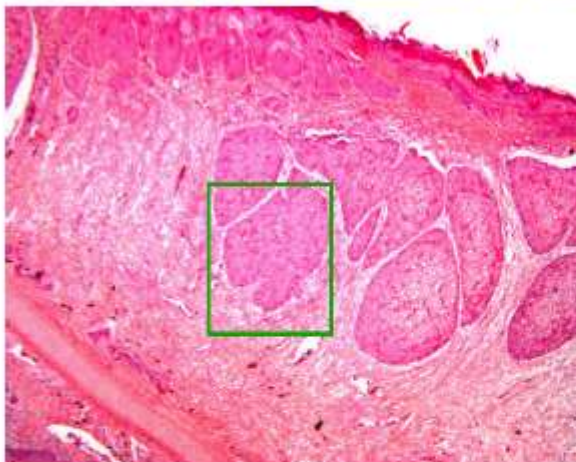
-  Histological lesions : Practical

- ◆ V7: Skin, Wild pigeon, adulte

- ◆ V8: Trachea, Hen, 52 weeks old

### NON TUMORAL AVIAN VIRAL DISEASES WITH INCLUSION BODIES

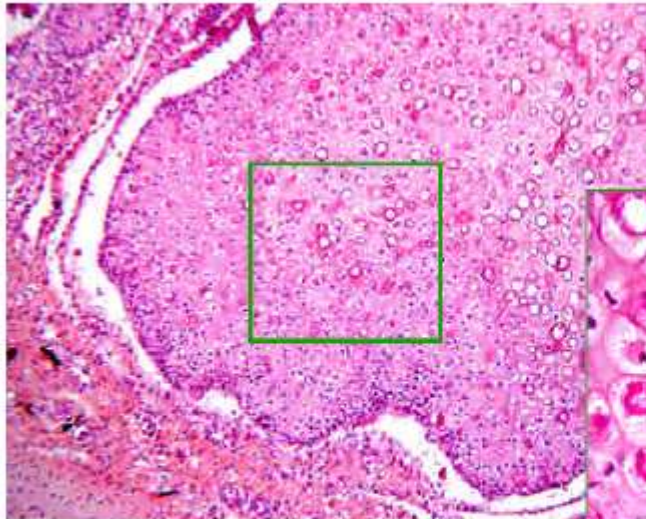
- V 7: Wild pigeon, adulte, skin (digit)



Multifocal to coalescent importante epidermal hyperplasia  
Hyperkeratosis with severe necrosis and exsudate (scabs)  
Dermal inflammatory infiltrate

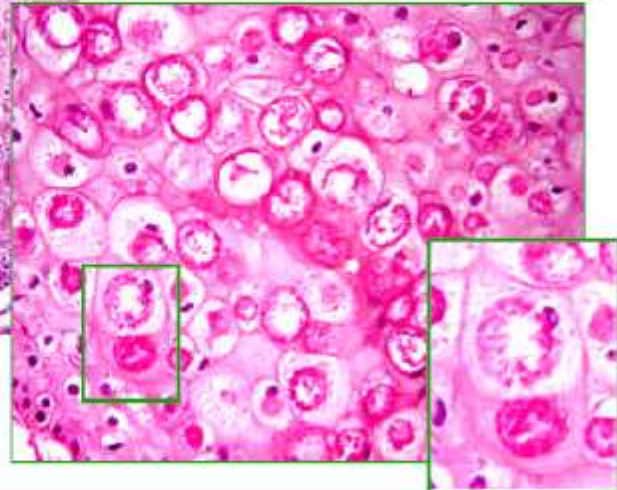
## NON TUMORAL AVIAN VIRAL DISEASES WITH INCLUSION BODIES

- V 7: Wild pigeon, adulte, skin (digit)



Ballooning degenerative epidermal cells with voluminous intracytoplasmic acidophilic inclusion bodies (Bollinger's bodies)

NB: Poxviruses = DNA viruses with intracytoplasmic inclusion bodies

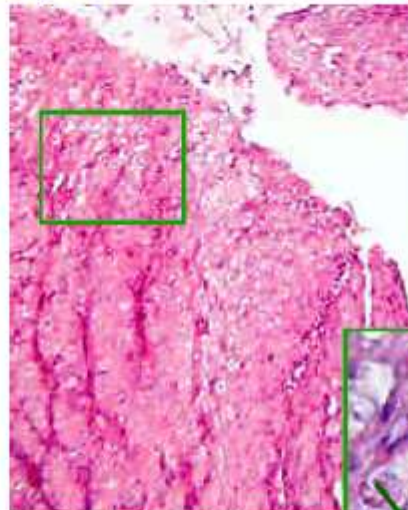
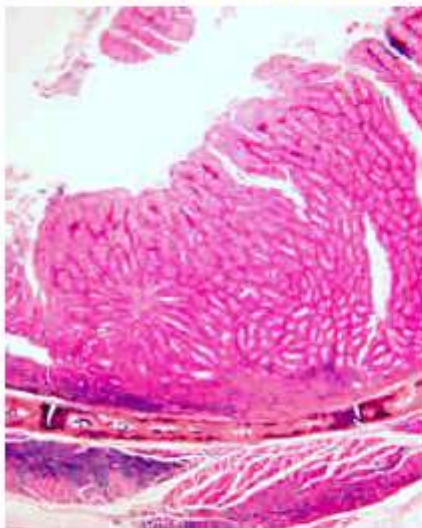


### Conclusion:

Severe, subacute, multifocal, exsudative and hyperplastic dermatitis with voluminous intracytoplasmic acidophilic viral inclusion bodies: Cutaneous Avian Poxvirus (Fowl Pox)

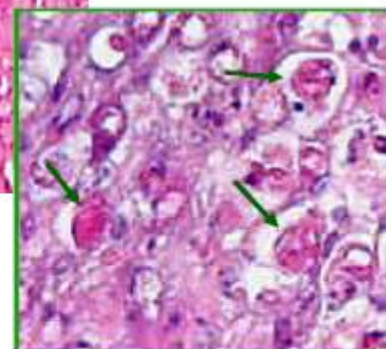
## NON TUMORAL AVIAN VIRAL DISEASES WITH INCLUSION BODIES

- V 6: Hen, 52 weeks old, Larynx



Voluminous, irregular, intracytoplasmic acidophilic inclusion bodies (Bollinger's bodies)

Epithelial Hyperplasia, epidermal Metaplasia  
Hyperemia and Inflammation, Moderate exudate



### Conclusion:

Severe, subacute, multifocal, hyperplastic (and exsudative) Laryngitis with voluminous intracytoplasmic acidophilic viral inclusion bodies : Mucosal Avian Poxvirus (Fowl Pox)

## **NON TUMORAL AVIAN VIRAL DISEASES WITH INCLUSION BODIES**

- **Avian Poxvirosis: Conclusion**

- ☑ **Same gross and histological lesions in every avian species**

- ☛ Cutaneous form and/or mucosal form
    - ☛ Histology: Epithelial **Hyperplasia** and **Metaplasia** with ± severe dermal and exsudative Inflammation
    - ☛ Voluminous **intracytoplasmic acidophilic inclusion bodies**: Bollinger's bodies