

Marie Curie Training Courses

Summer School 2007 – Avian V11/V12

NON TUMORAL AVIAN VIRAL DISEASES WITHOUT INCLUSION BODIE

- Association of lesions

- ☒ Avian Encephalomyelitis: Histology: Practical

- ☛ V11: Chicken, 14 days old, CNS

- ☛ V12: Same chicken, various organs

NON TUMORAL AVIAN VIRAL DISEASES WITHOUT INCLUSION BODIES

- Association of lesions

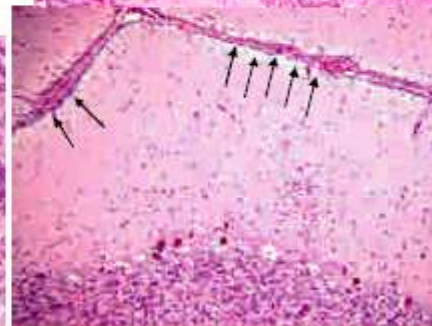
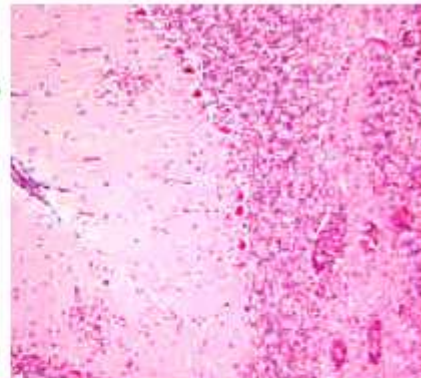
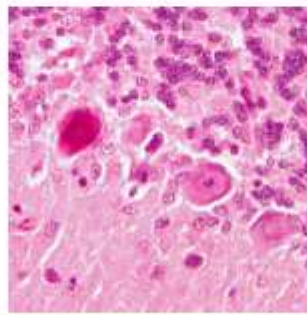
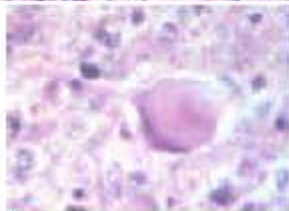
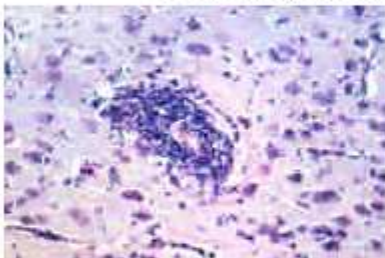
- ☒ Avian Encephalomyelitis: Histology, CNS

- ☛ All portions of brain and spinal cord

- ☛ Perivascular infiltrates

- ☛ Gliosis

- ☛ Chromatolysis and neuronal necrosis



Conclusion :

Disseminated non purulent (viral) encephalomyelitis

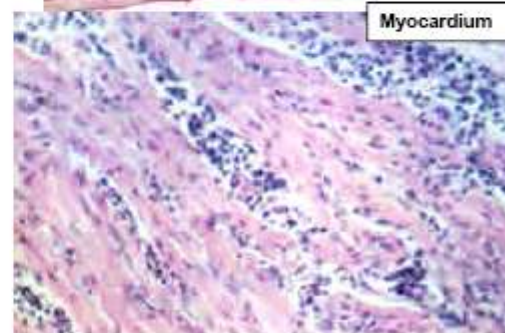
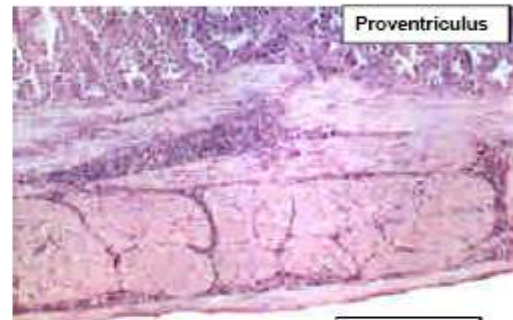
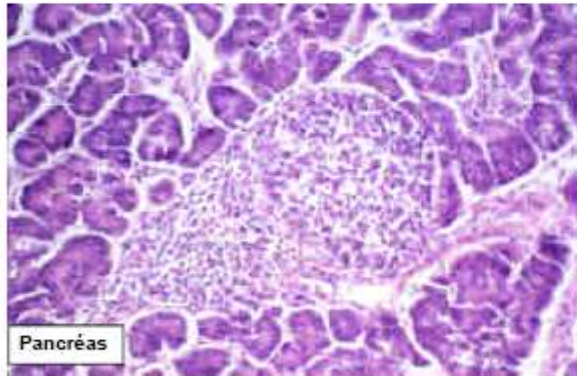
Be careful, in chick, the immature brain shows a regular line of migrating glial cells near the meninges

NON TUMORAL AVIAN VIRAL DISEASES WITHOUT INCLUSION BODIES

- Association of lesions

- ☒ Avian Encephalomyelitis: Histology, Visceral lesions

- ↪ Numerous organs : pancreas, myocardium, muscular layer of proventriculus and gizzard
 - ↪ Hyperplasia of normal lymphoid aggregates
 - ↪ Hyperplasia of visceral lymphoid follicles



Conclusion :

Multifocal, hyperplasia of visceral lymphoid aggregates and follicles

NON TUMORAL AVIAN VIRAL DISEASES WITHOUT INCLUSION BODIES

- Association of lesions

- ☒ Avian Encephalomyelitis: Lesions Specificity

- ↪ Association of 2 types of histological lesions

- ◆ Disseminated non purulent (viral) encephalomyelitis
 - ◆ Multifocal hyperplasia of visceral lymphoid aggregates and follicles

- ↪ Associated with:

- ◆ Epidemiology: Epidemic nervous syndrome in young chickens (1-2 weeks)
 - ◆ Clinical Signs: quick onset with tremors, ataxia and paralysis