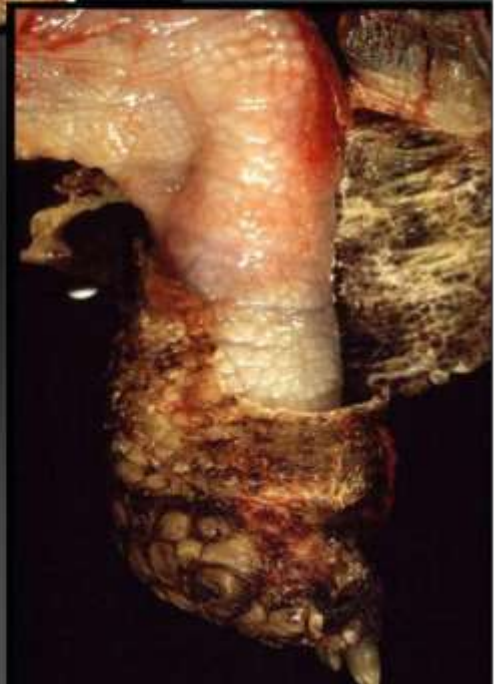
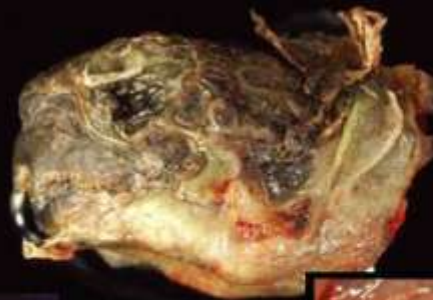
Marie Curie Training Courses

Summer School 2004 – Reptile Case 13

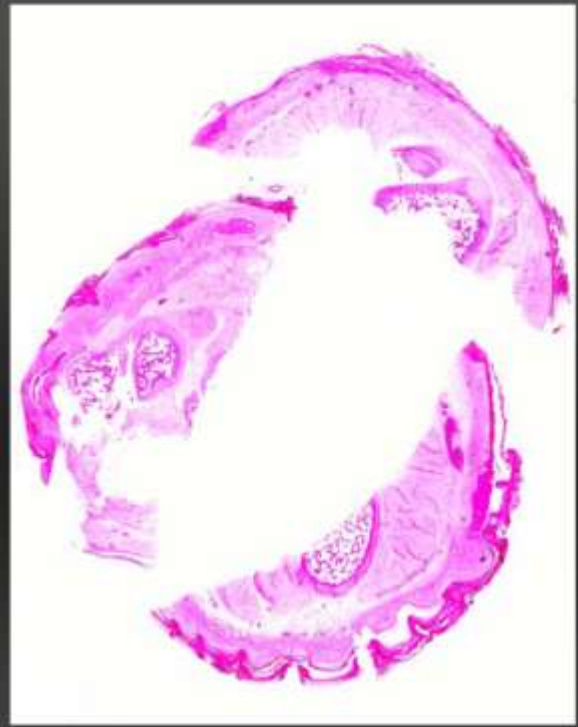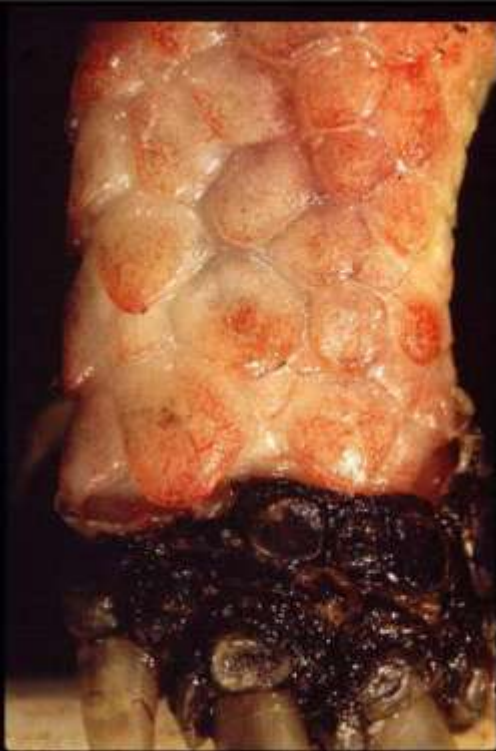13 Tortoise

Testudo graeca

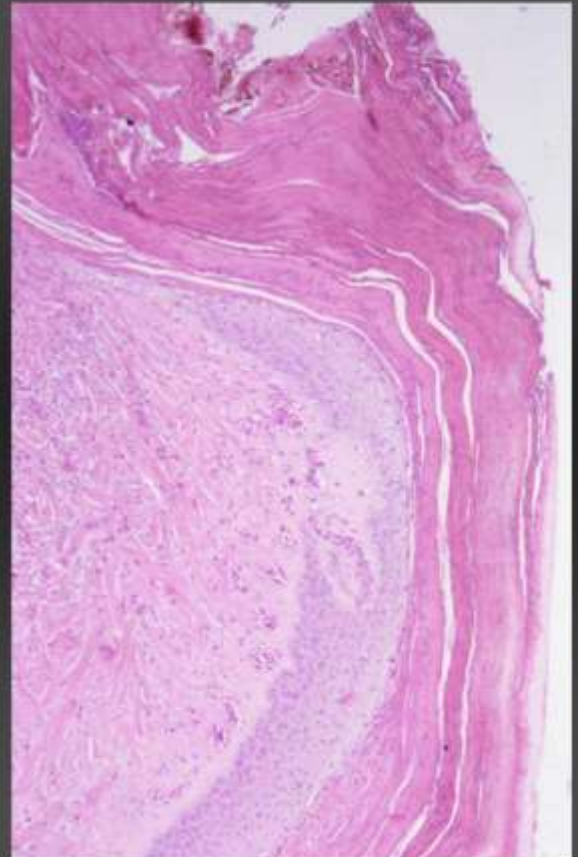
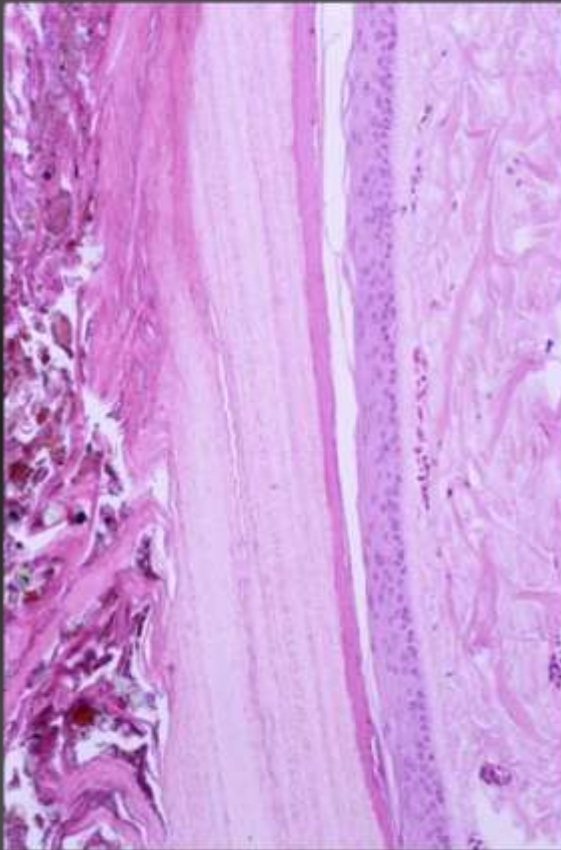


13 Tortoise

Testudo graeca



13 Tortoise Skin



13 Tortoise

Morphologic diagnoses:

Skin:

moderate orthokeratotic and parakeratotic hyperkeratosis

with numerous fungal hyphae
(c.f. *Aspergillus* sp.)

focal, pyogranulomatous, ulcerative dermatitis

Aetiologic Diagnoses:

vitamin A hypervitaminosis

dermal mycosis (? secondary)

