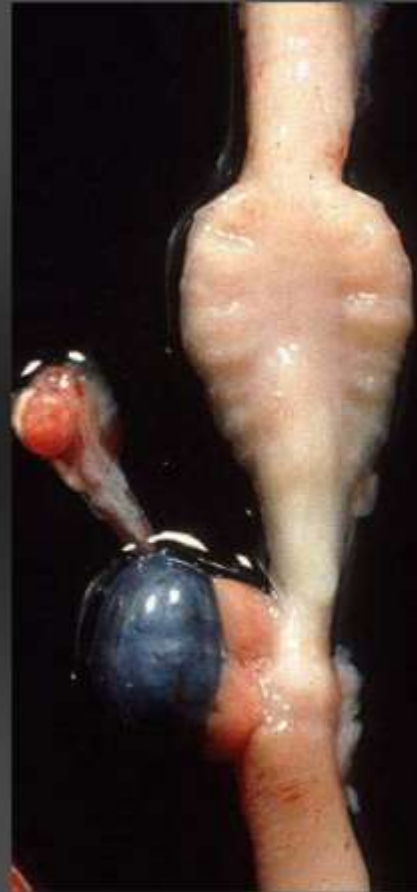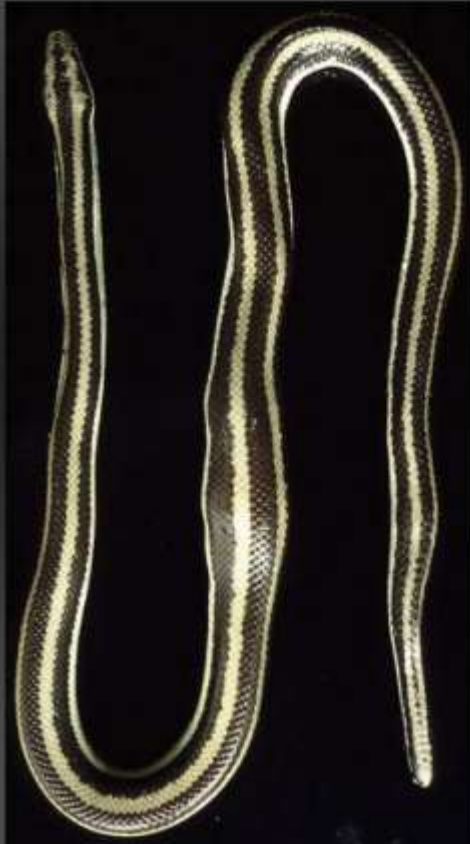


Marie Curie Training Courses

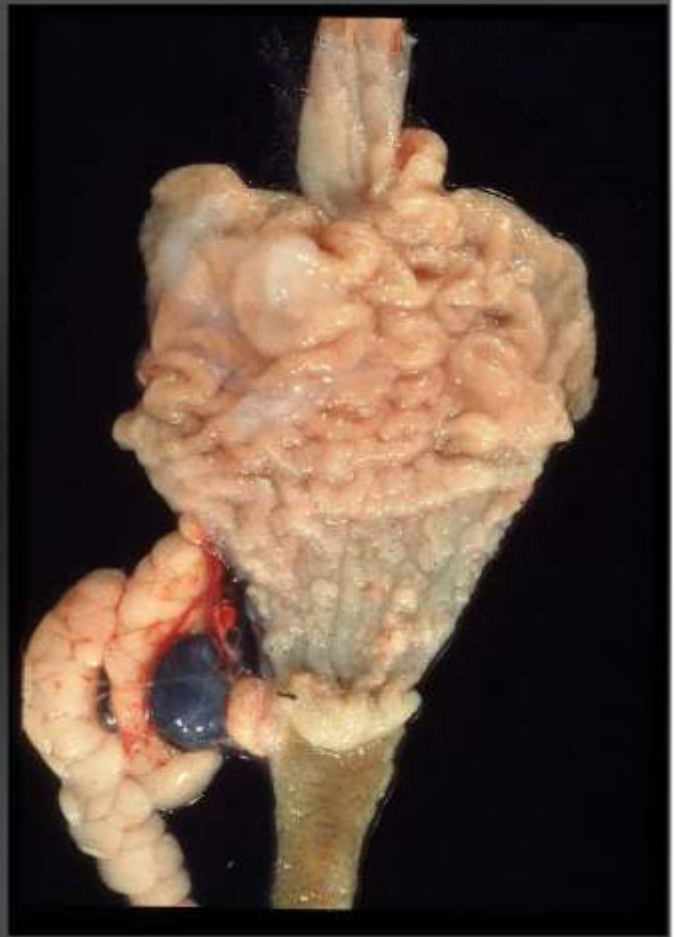Summer School 2004 – Reptile Case 17

17 Snake
Lichanura sp.



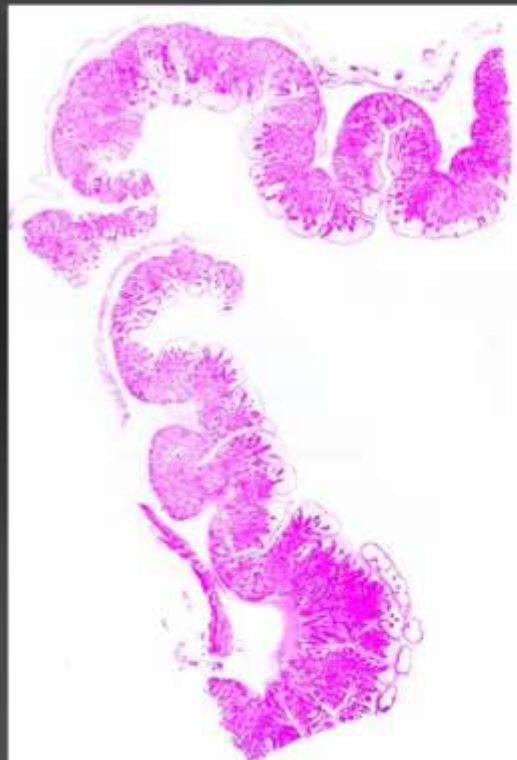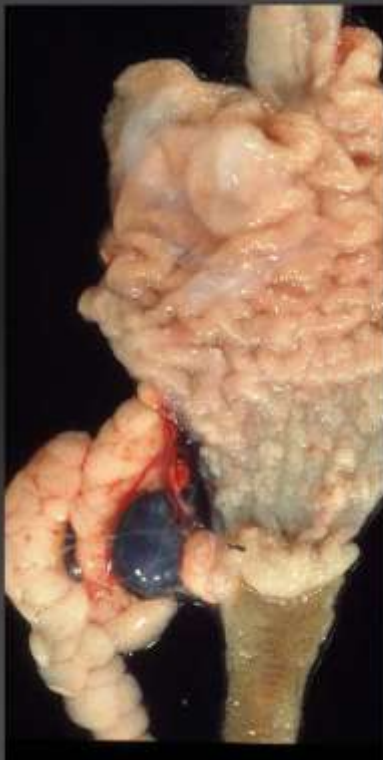17 Snake

Epikrates sp.



17 snake

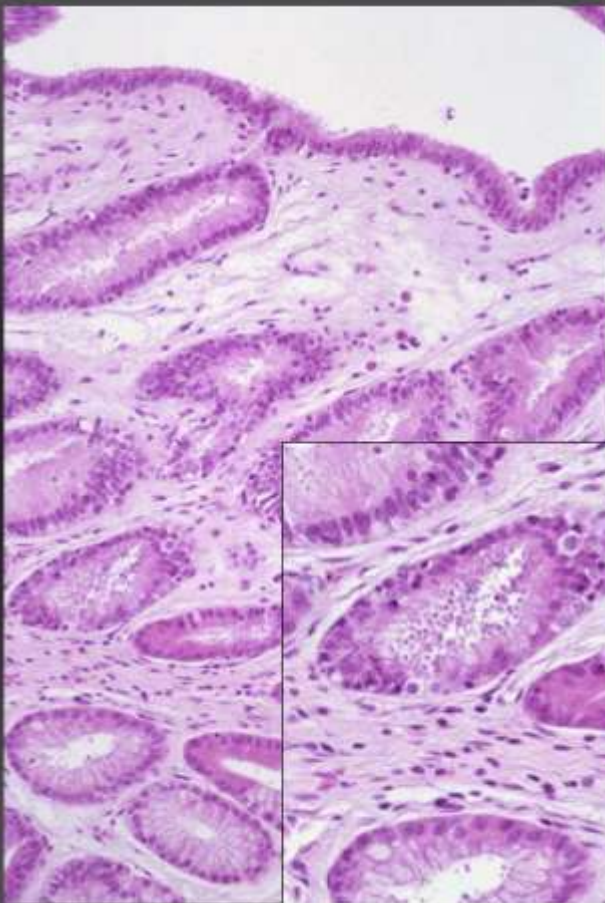
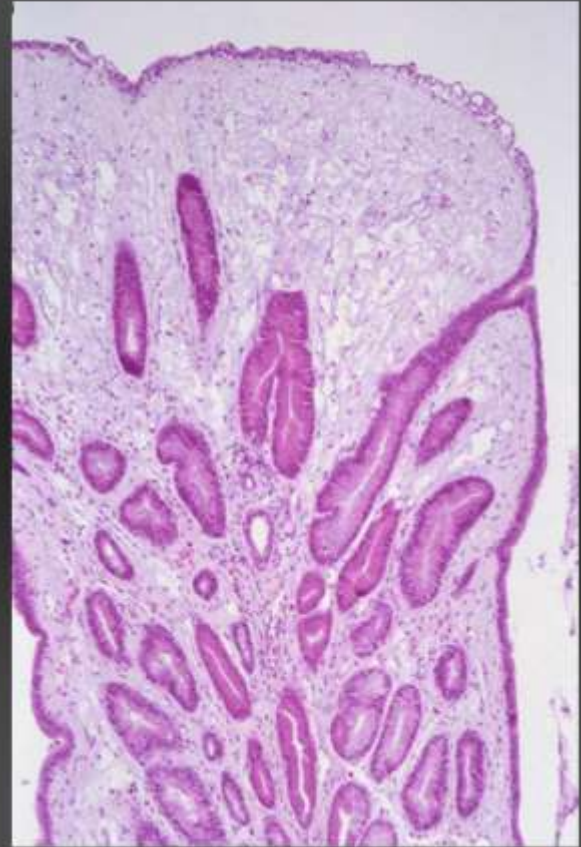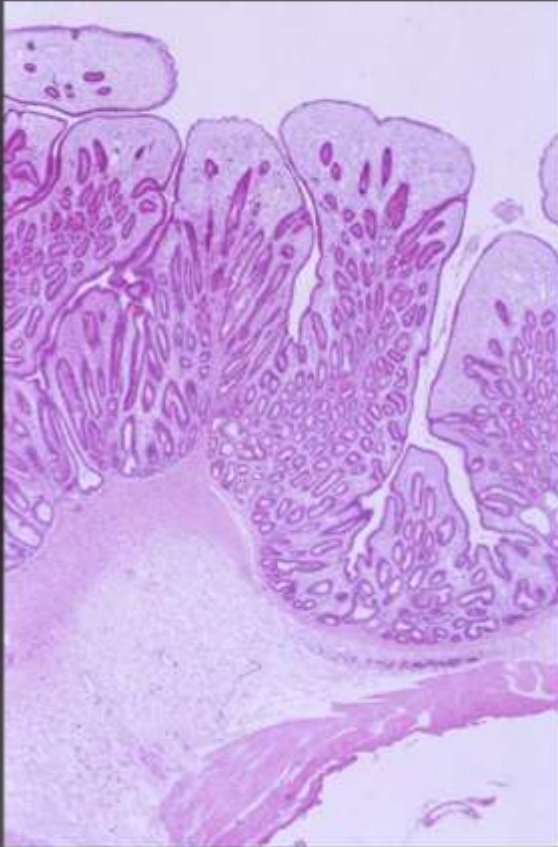
Lichanura sp. / *Epikrates* sp.
stomach



17 Snake

Lichanura sp.

stomach



17 Snake

Lichanura sp.

Morphologic diagnoses:

Stomach:

glandular hyperplasia, severe diffuse

chronic heterophilic and lympho-plasmacytic
gastritis with fibrosis

Aetiologic diagnosis:

Cryptosporidiosis

c.f. *C. serpentis*