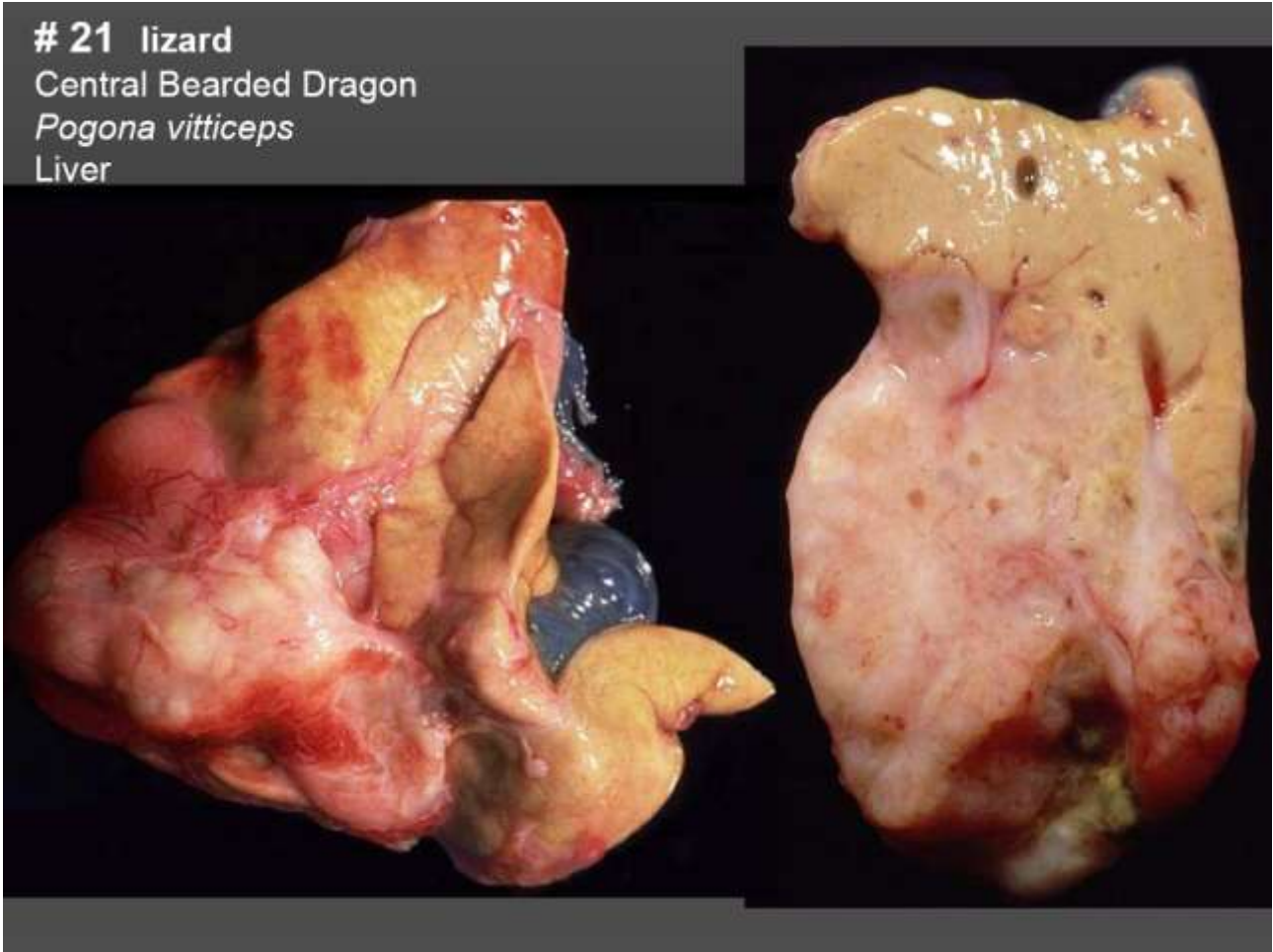

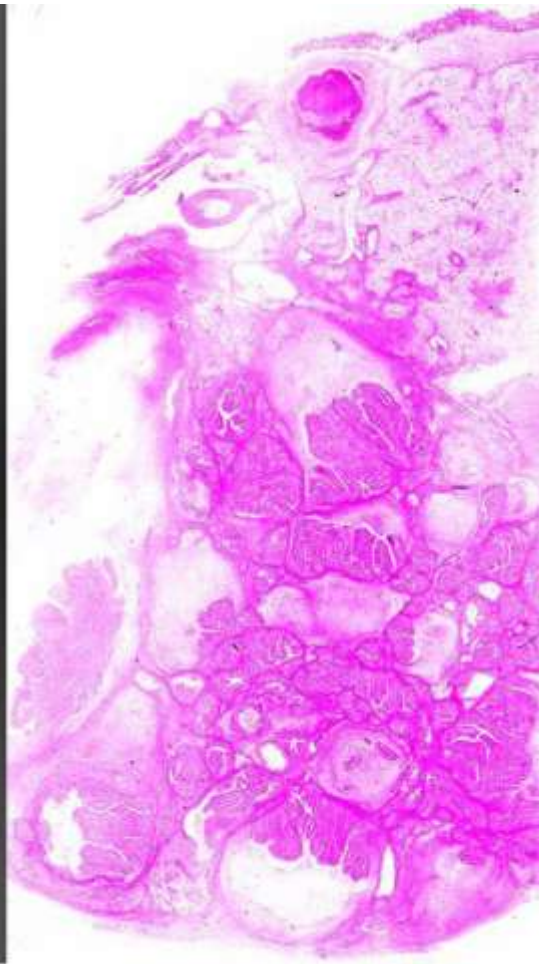
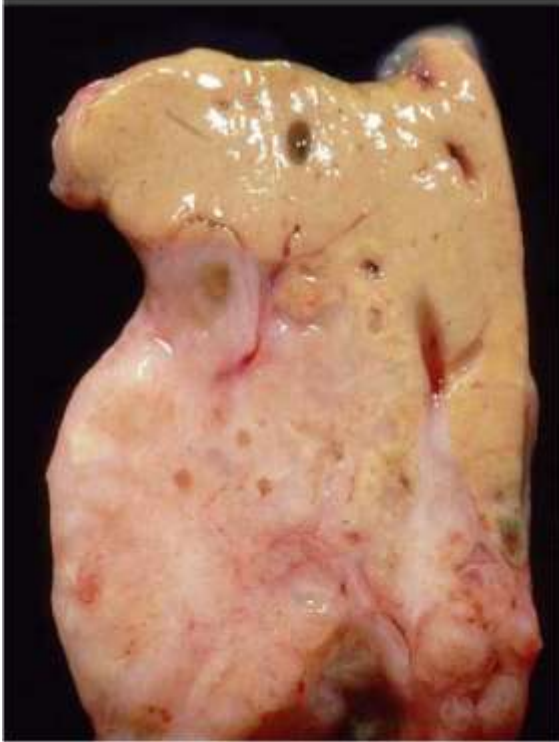## Marie Curie Training Courses

Summer School 2004 – Reptile Case 21

# 21 lizard  
Central Bearded Dragon  
*Pogona vitticeps*  
Liver

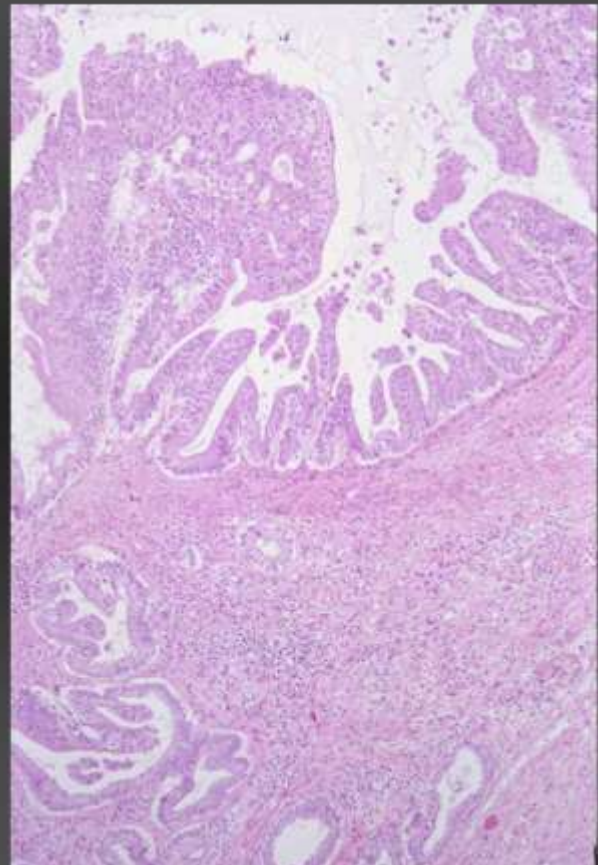
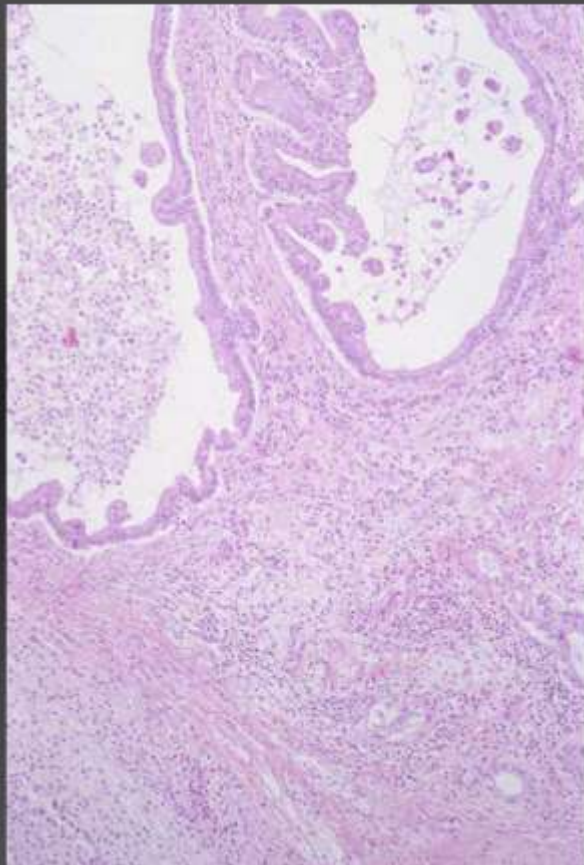


# 21 lizard  
Central Bearded Dragon  
*Pogona vitticeps*  
Liver

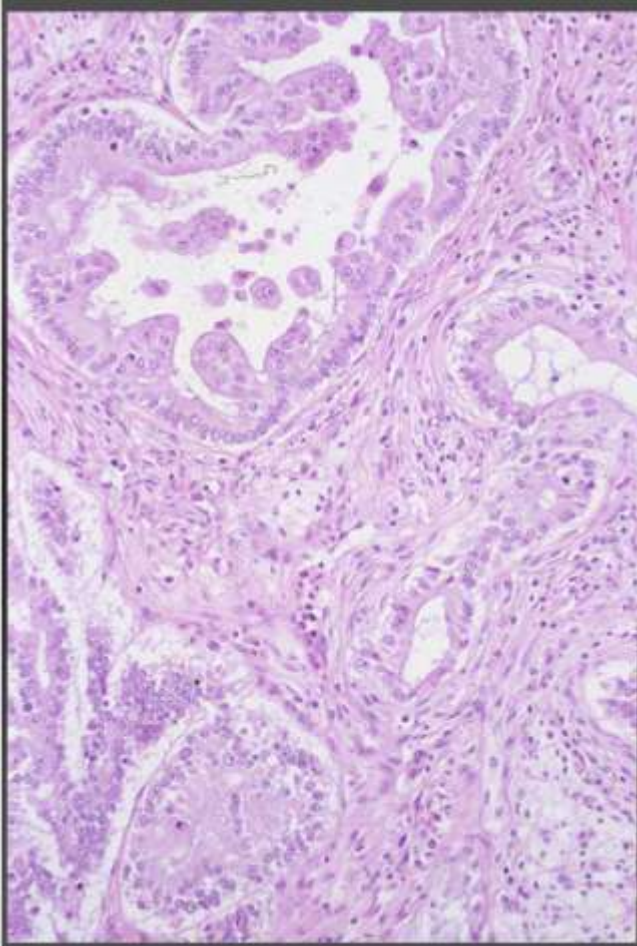


# 21 lizard Central Bearded Dragon

liver







# 21 lizard  
Central Bearded Dragon

*Morphologic diagnosis:*

Liver: cholangial carcinoma

pyogranulomatous hepatitis (with abscess formation), focal, moderate

fatty degeneration, diffuse, severe

Aetiologic diagnosis: none

